EEG E STEREO-EEG

LAURA TASSI – CENTRO CHIRURGIA EPILESSIA «CLAUDIO MUNARI»

ASST GOM NIGUARDA - MILANO

Lunedì 25 ottobre

Moderatori:
Adriana Magaudda (Messina) – *Mario Zappia* (Catania)

09:00 – 10:00	Manifestazioni ed EEG nel bambino *Nicola Specchio* (Roma)
10:00 – 11:00	Manifestazioni ed EEG nell'adulto *Stefano Meletti* (Modena)
11:00 – 11:20	*Pausa*
11:20 – 12:20	Video session *Giuseppe d'Orsi* (Andria)
12:20 – 13:20	EEG e Stereo-EEG *Laura Tassi* (Milano)



CORSO VIDEO EEG LICE
3° EDIZIONE
CATANIA, 24-27 OTTOBRE 2021

Stereo-EEG

EPILEPTOGENIC ZONE

Defined on the basis of anatomo-electro-clinical correlations

Cortical area/areas:

- in which ictal discharges originate?
- whose removal cure the patient?
- anatomical lesion?
- symptomatogenic zone?

Anatomo-electro-clinical Correlations

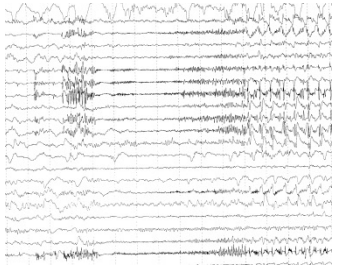

Video-EEG Data

Neuroradiological Data

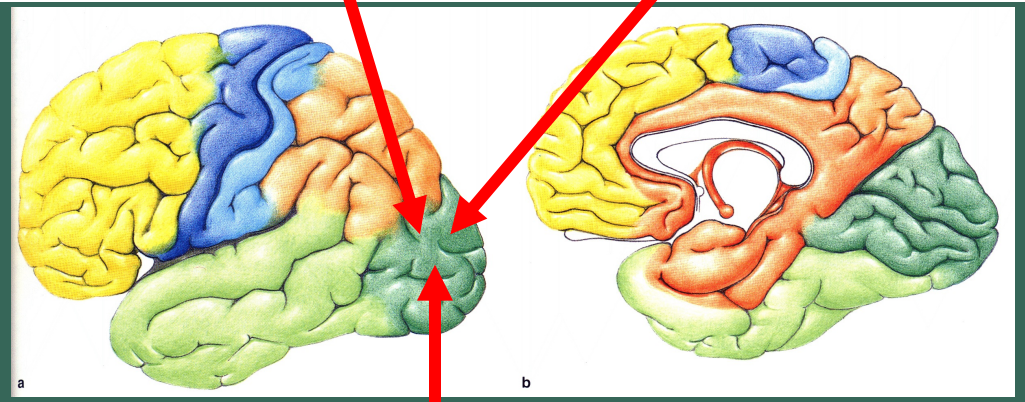

Clinical data

The Patient

Clinical data

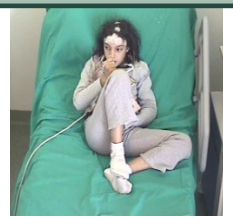

Neuro radiology

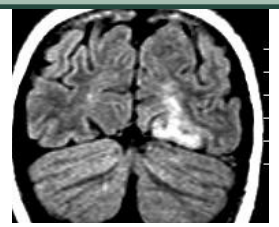

Interictal EEG

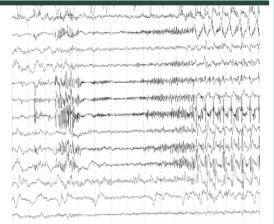

Neuropsychology
Ancillary exams

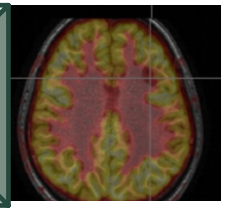

45%

VEEG

35%

iEEG

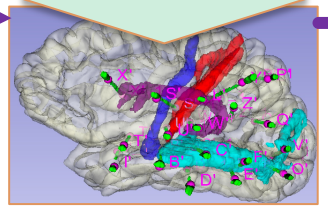

20%

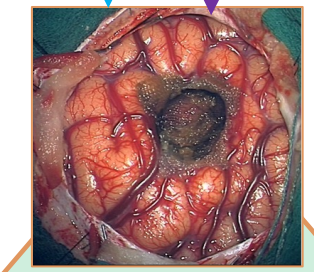

Surgery

Epilepsy Surgery: presurgical workflow

Once upon a time…

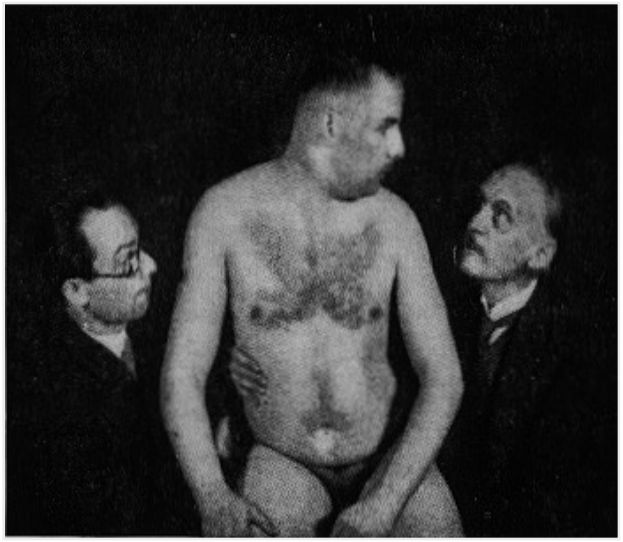

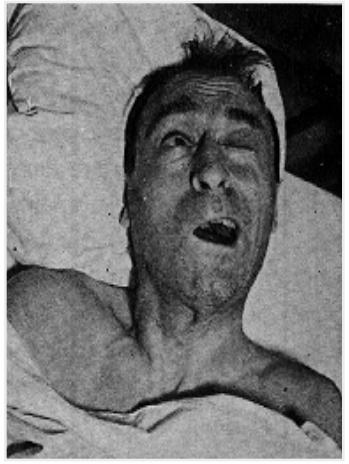

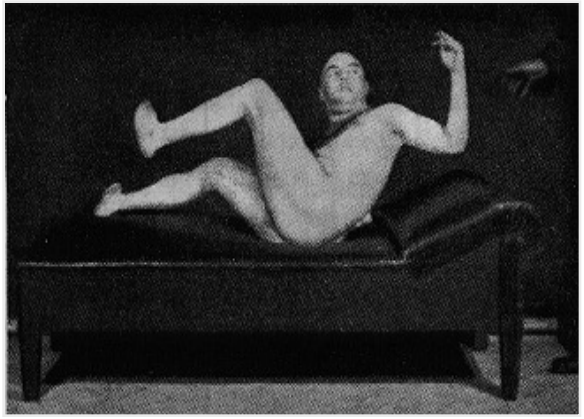

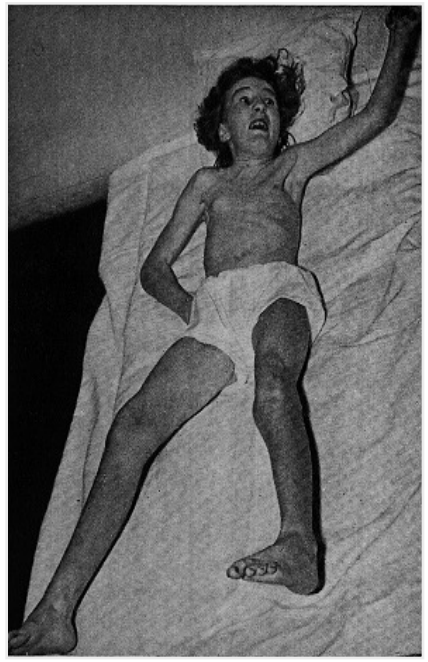

Stereo-EEG
Analysis and interpretation

Lesional Area: slow waves, background activity absent

Irritative Area: spikes, spikes and waves

Functional Area: electrical stimulations

Epileptogenic Area

Interictal paroxysms
Spontaneous seizures
Electrical stimulations
……

EZ and invasive recordings: how many regions?

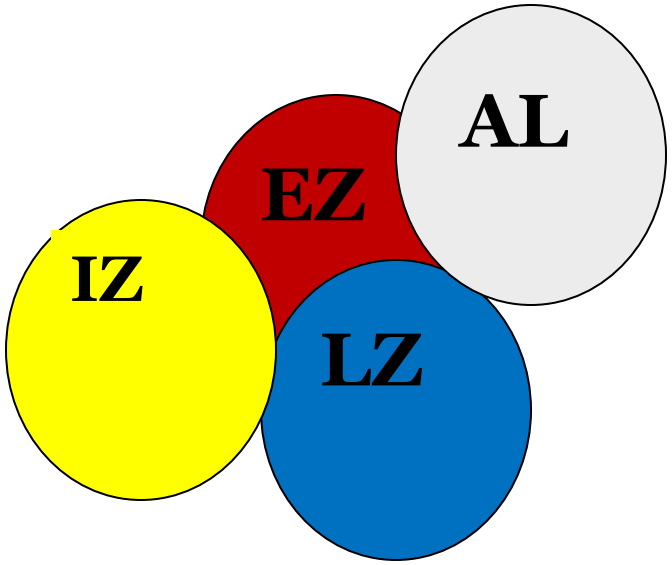

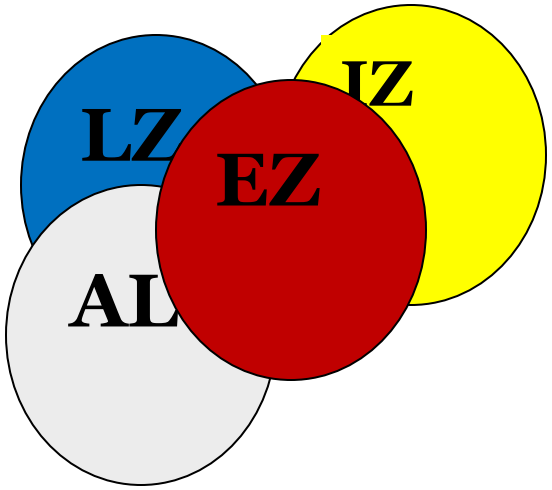



AL: anatomical lesion
LZ: lesional zone
IZ: irritative zone
EZ: epileptogenic zone

Indications and utilityof Stereo-EEG

- discrepancies between:
  - anatomical and clinical data;
  - anatomical and electrical data;
  - electrical and clinical data;
- supposed bi- or multi-lobar ictal discharges;
- early ictal involvement of functional cortical areas (suggested by the clinical semiology);

1. Individually tailored surgical removal
2. THC: Thermocoagulation


Distance:
1.5 mm
Contact:
2.0 mm
Diameter
0.8 mm

Concerning the observation of an electrical potential at a distance from an intracranial electrode contact

Hitten P. Zaveri, Robert B. Duckrow, Susan S. Spencer

Clinical Neurophysiology 120 (2009) 1873–1875

The source???

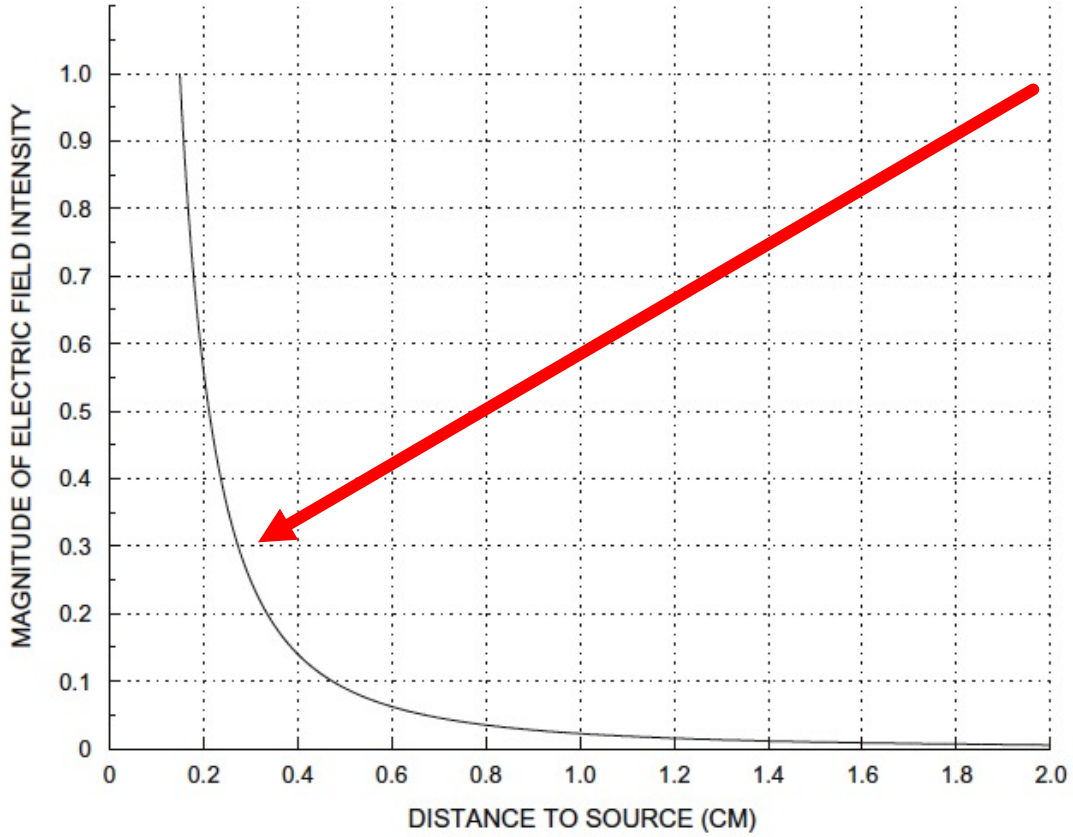

Fig. 1. The magnitude of the electric field intensity as a function of distance from a point charge. In this evaluation a charge is assumed to result in an electric field intensity of magnitude 1 at a distance of 0.15 cm. The magnitude of the electric field intensity decreases dramatically as a function of distance; the decrease in the magnitude of the electric field intensity is specified by the inverse-square law.

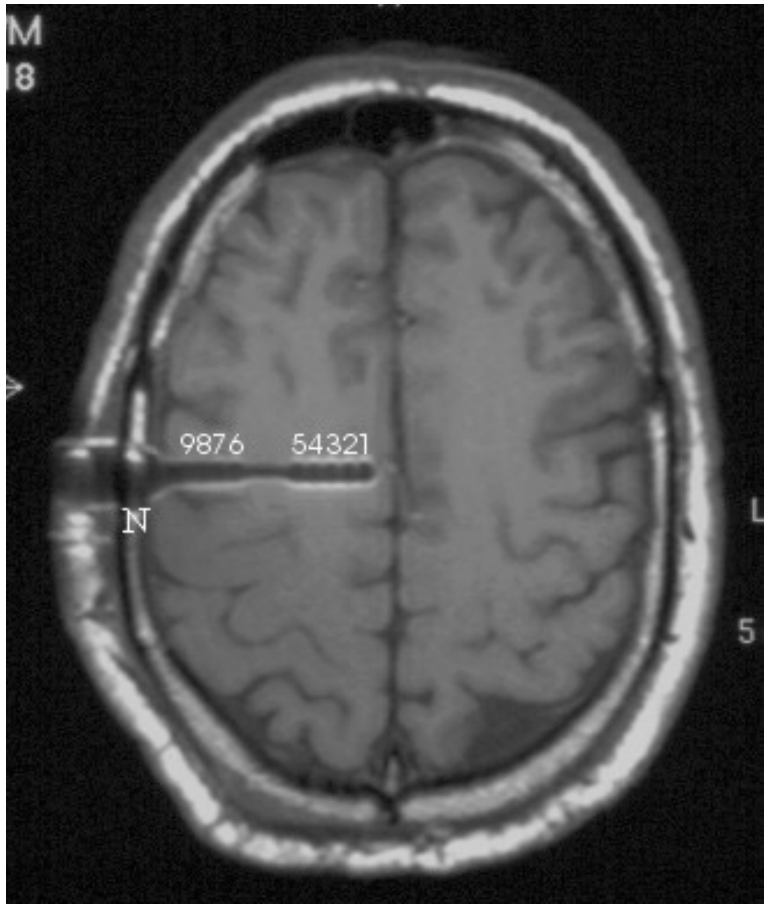
M
18
9876
54321
N

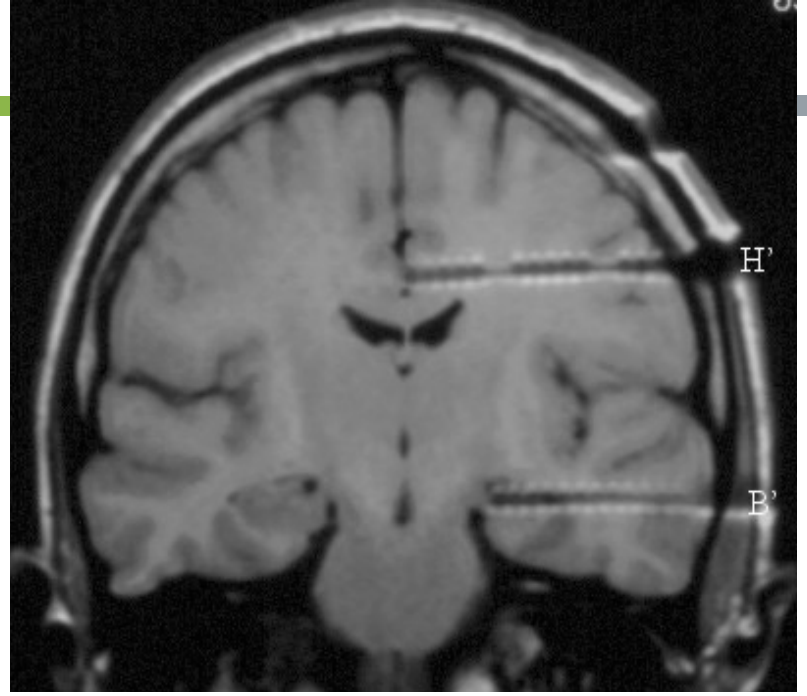
H'
B'

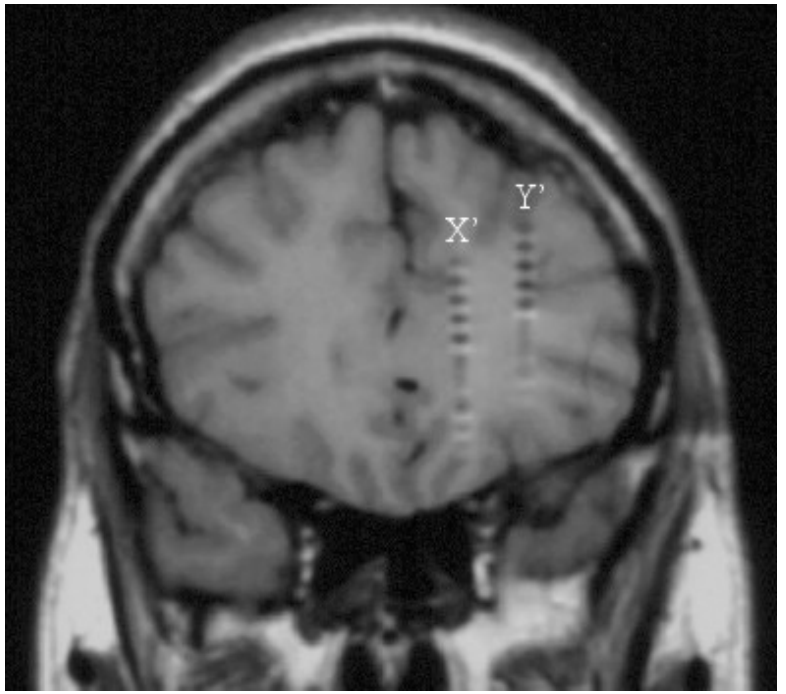
Y'
X'

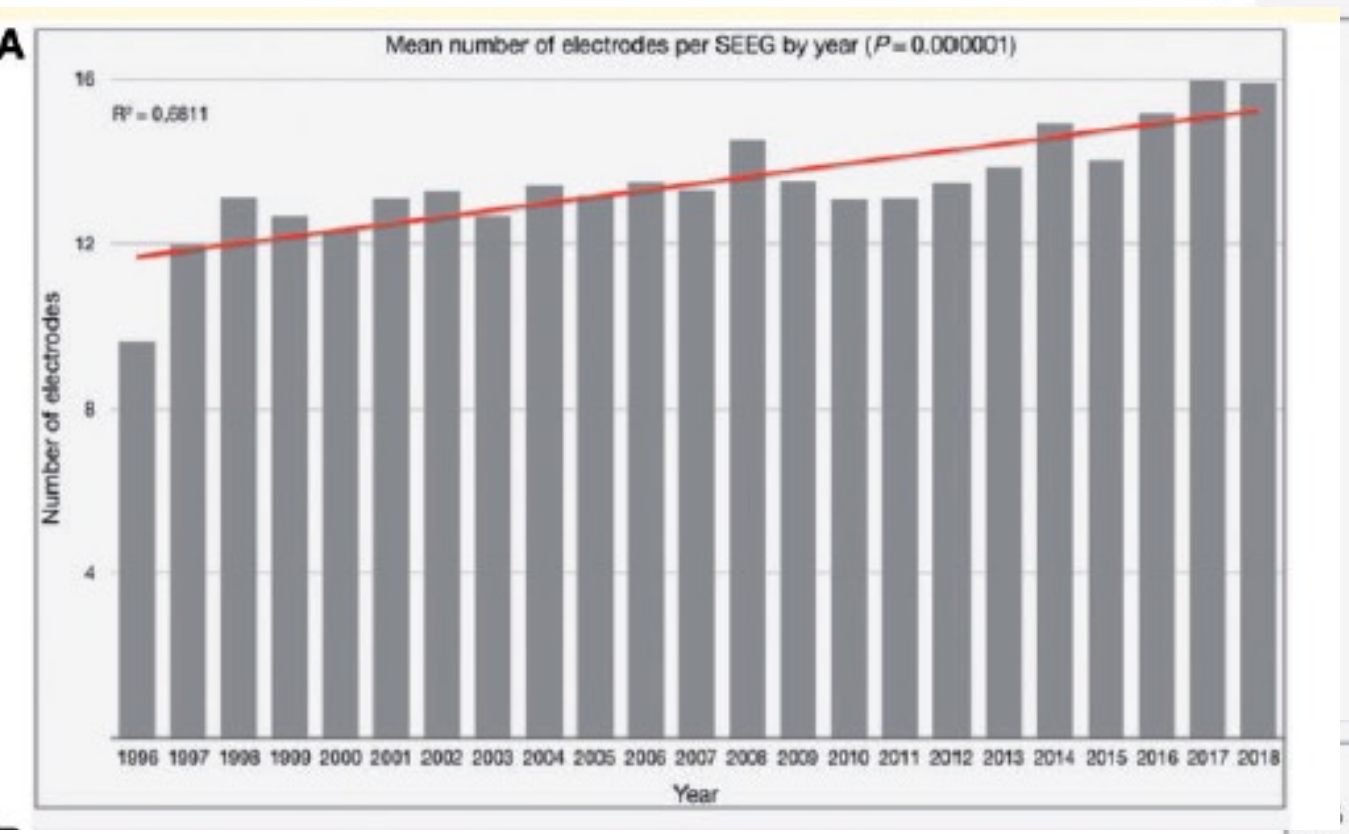

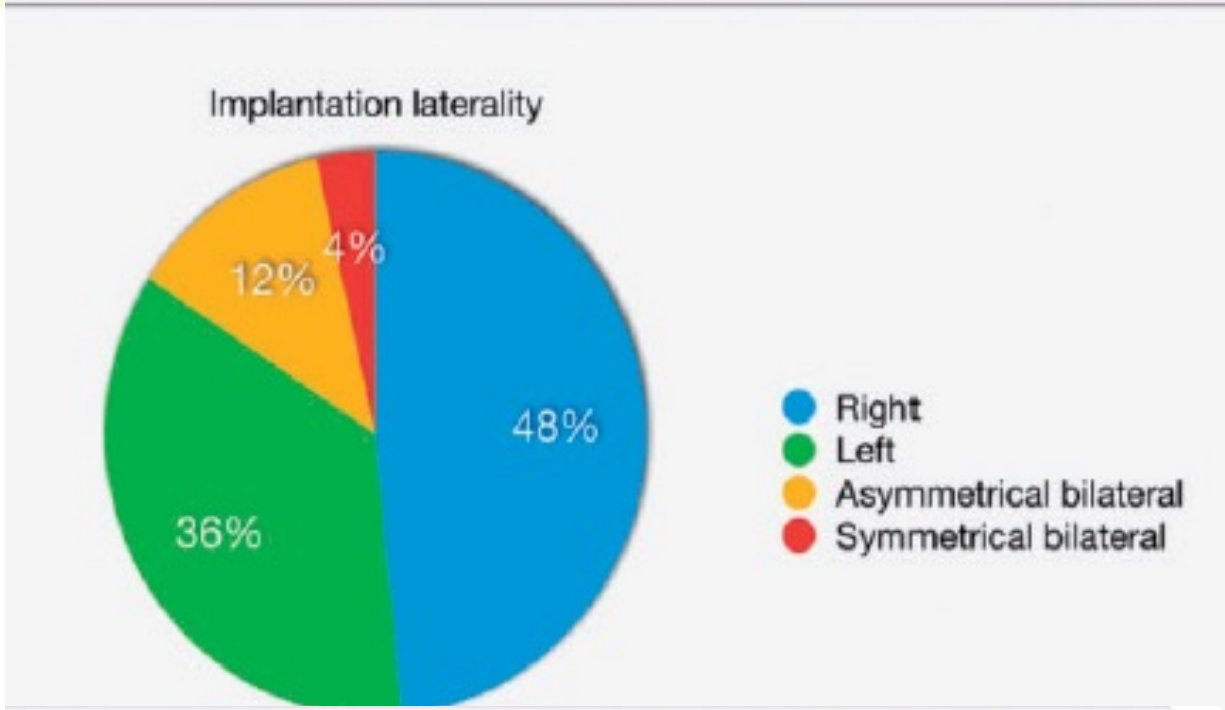

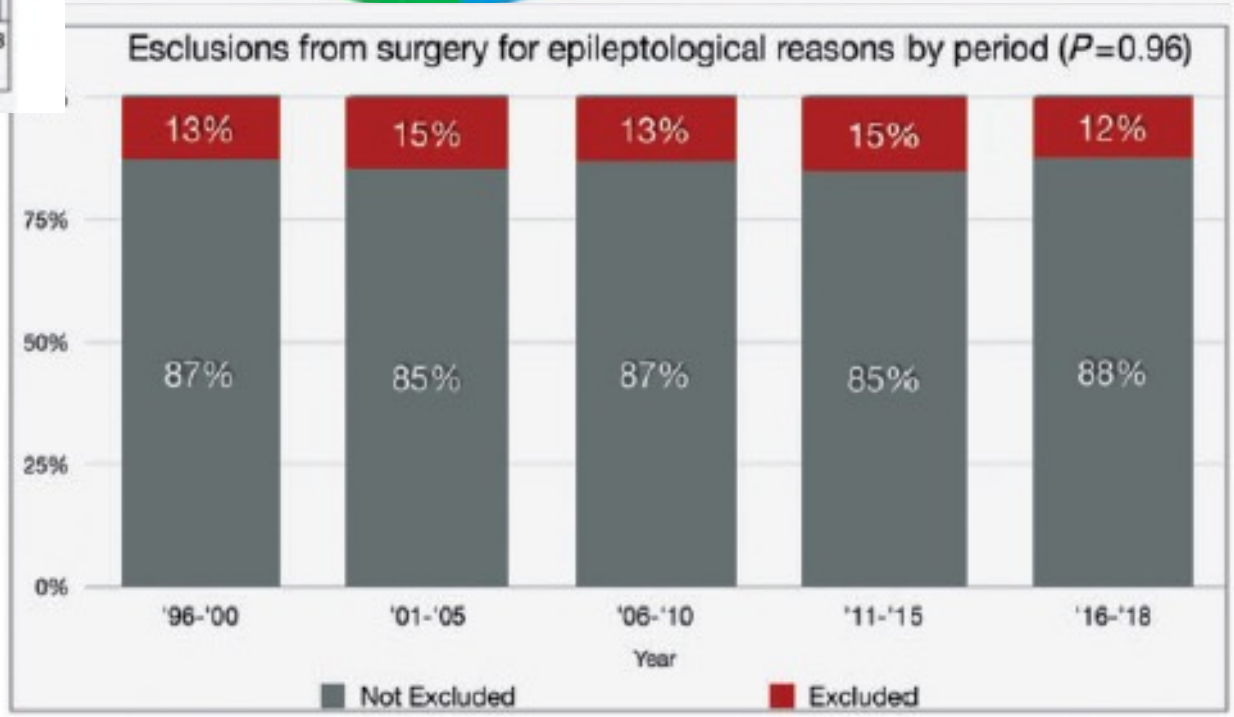

Brain 2019, Cardinale et al.

HS: hippocampal sclerosis
GT: glioneuronal tumors
FCD II: Focal Cortical Dysplasia Tipe II
FCD I: Focal Cortical Dysplasia Type I

Brain 2019, Cardinale et al.

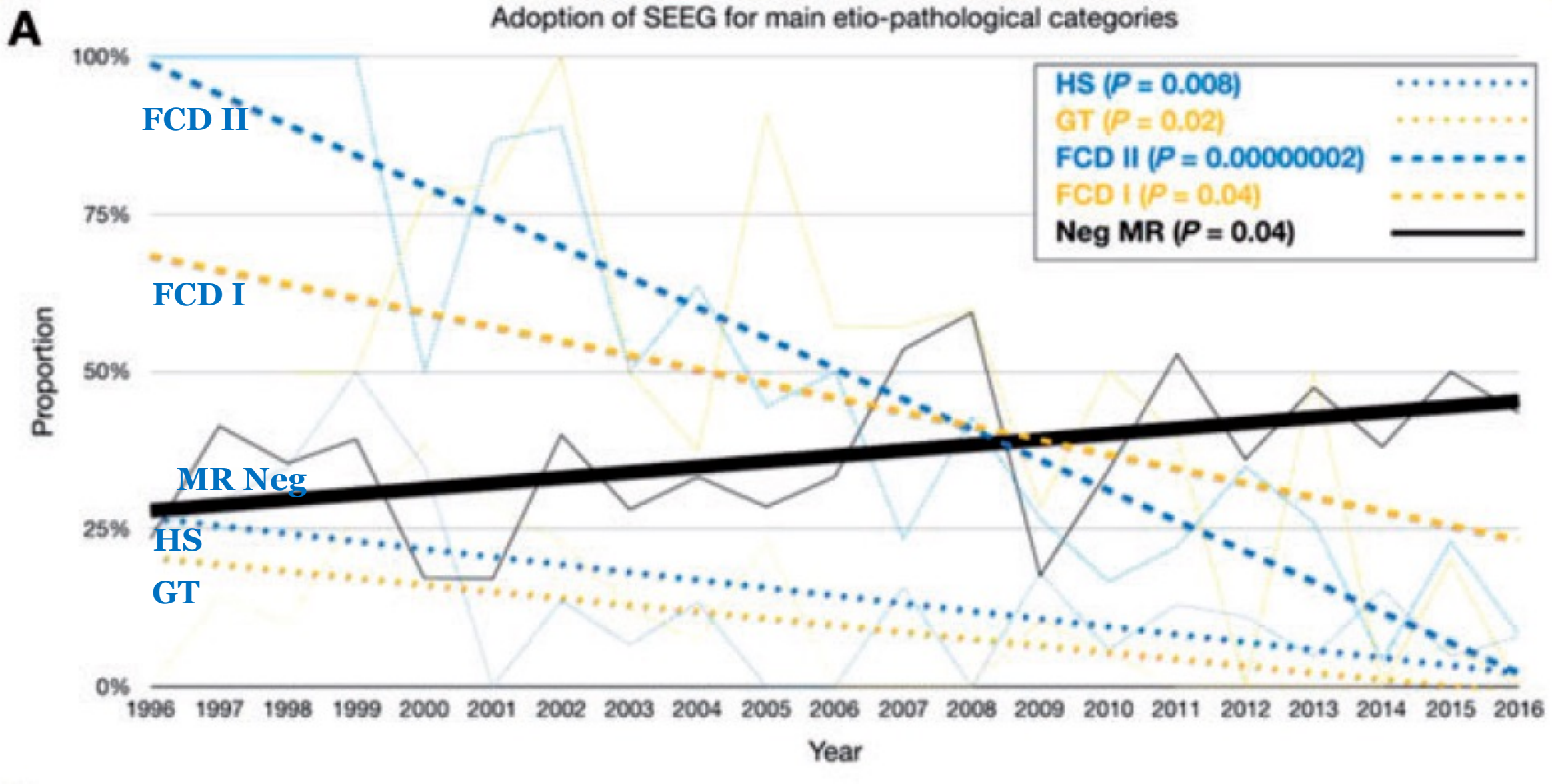

What did we learn over the past 30 years?

HINTS

1. Not all patients need invasive recordings (HS, FCD II, tumors)
2. The temporal lobe is different from all other lobes
3. Always look for the low voltage fast activity
4. Archicortex not able to produce LVFA (Hippocampus, Amygdala, Cingulum)
5. Better to think in terms of networks than cortical structures
6. Need to know the actual position of the electrodes
7. Intracerebral stimulations are essential for the mapping and definition of EZ
8. Some etiologies, however, require invasive recordings (PMG, PNH, scars)
9. Thermocoagulation is useful for healing but also for prognosis

Received: 6 July 2018 | Revised: 8 October 2018 | Accepted: 29 October 2018
DOI: 10.1111/epi.14610

Epilepsia

FULL-LENGTH ORIGINAL RESEARCH

Two main focal seizure patterns revealed by intracerebral electroencephalographic biomarker analysis

Vadym Gnatkovsky[1] | Veronica Pelliccia[2] | Marco de Curtis[1] | Laura Tassi[2]

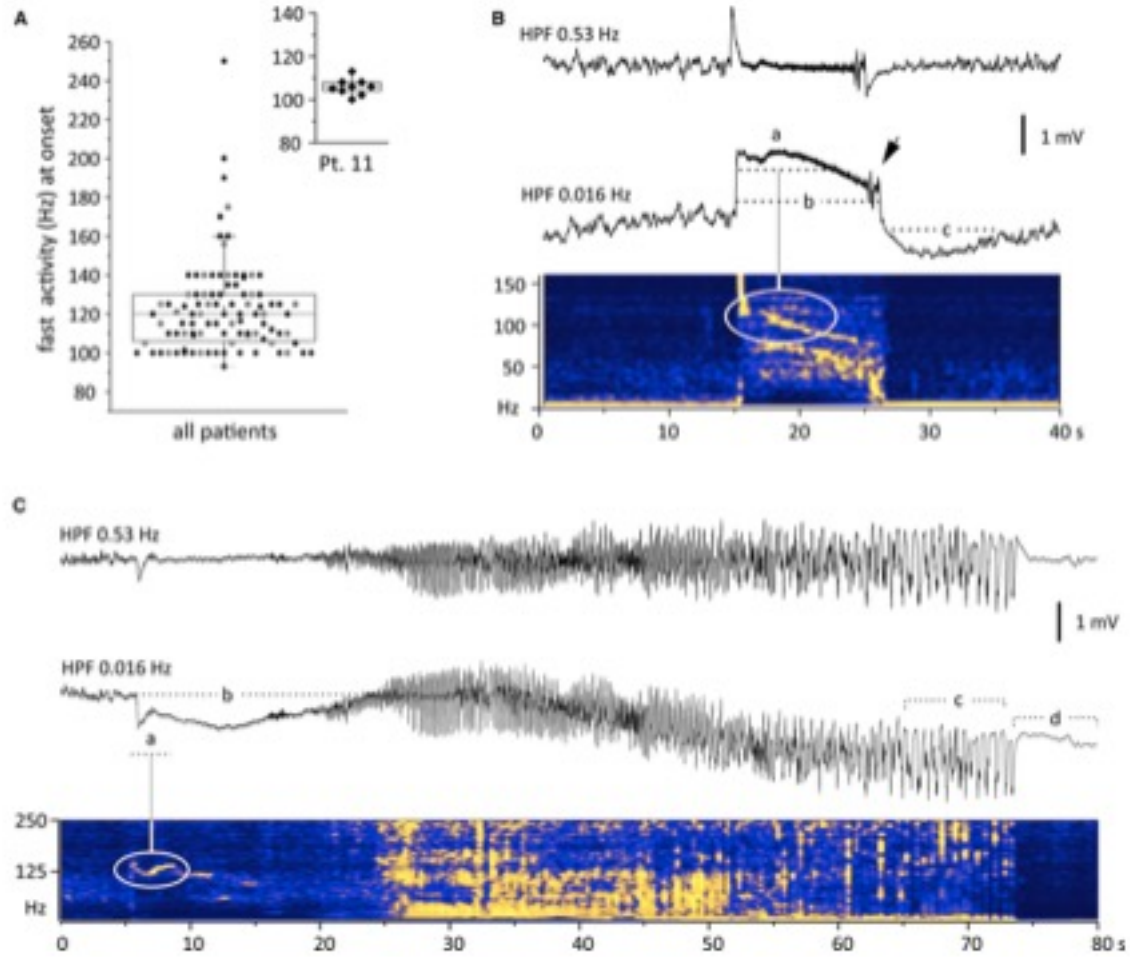

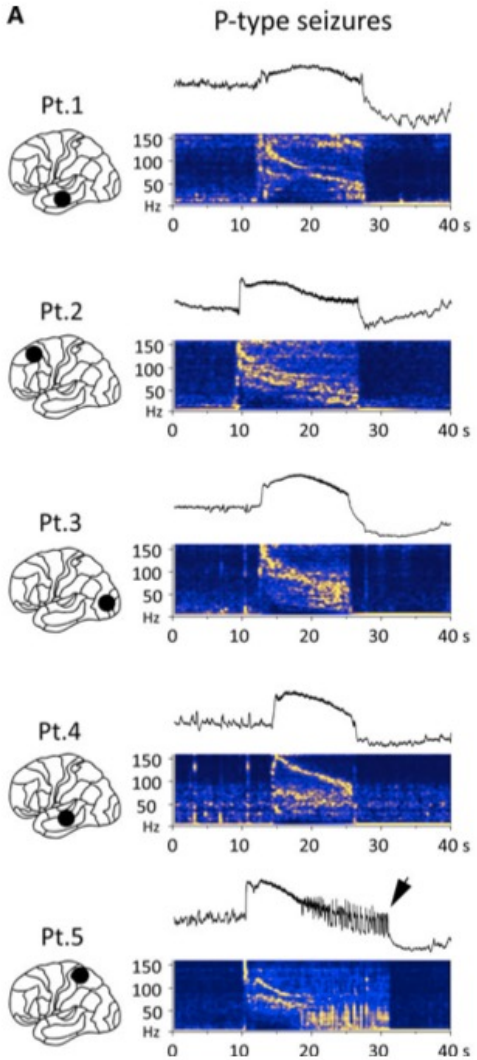

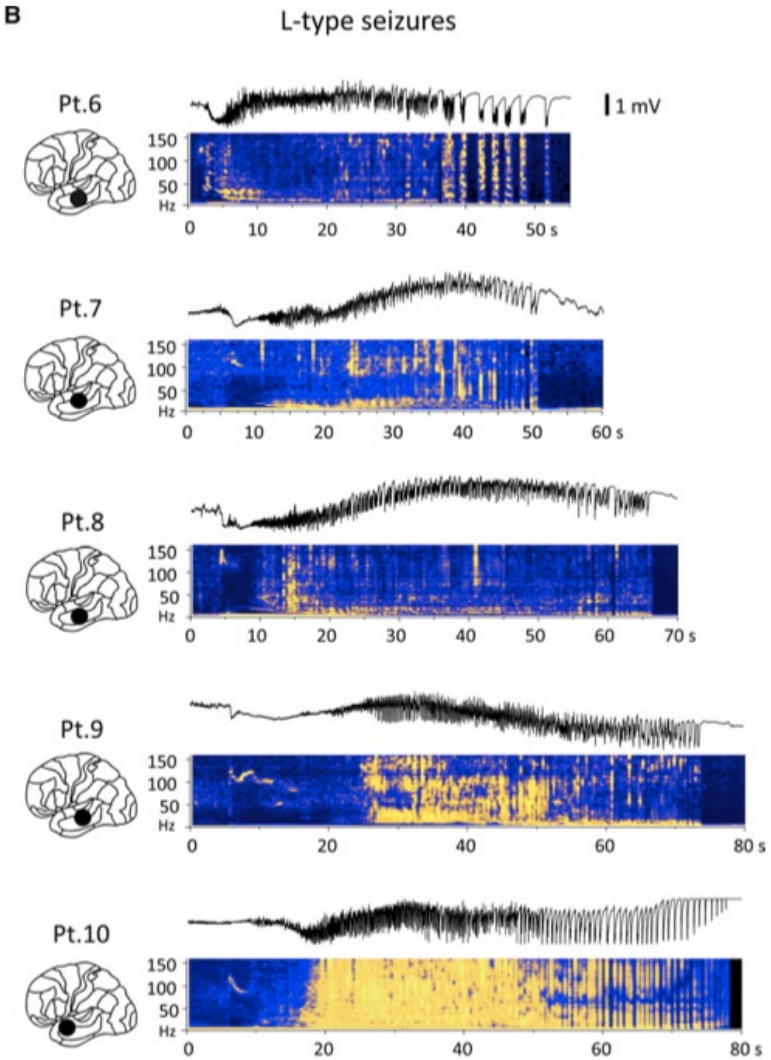

The past

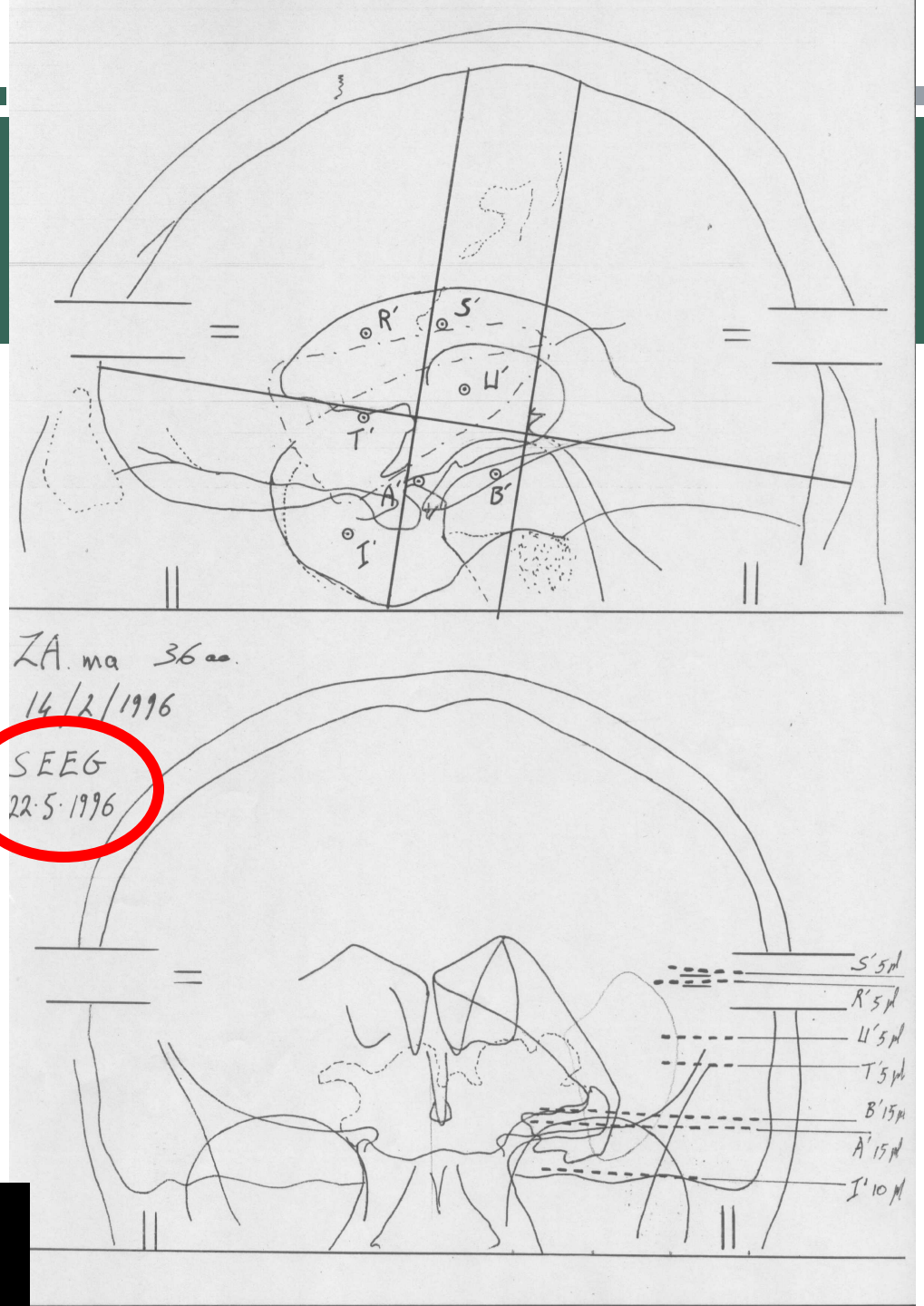
R'
S'
H'
T'
A'
B'
I'
ZA. ma 36 aa.
14/2/1996
SEEG
22·5·1996
S' 5 M
R' 5 M
H' 5 M
T' 5 M
B' 15 M
A' 15 M
I' 10 M

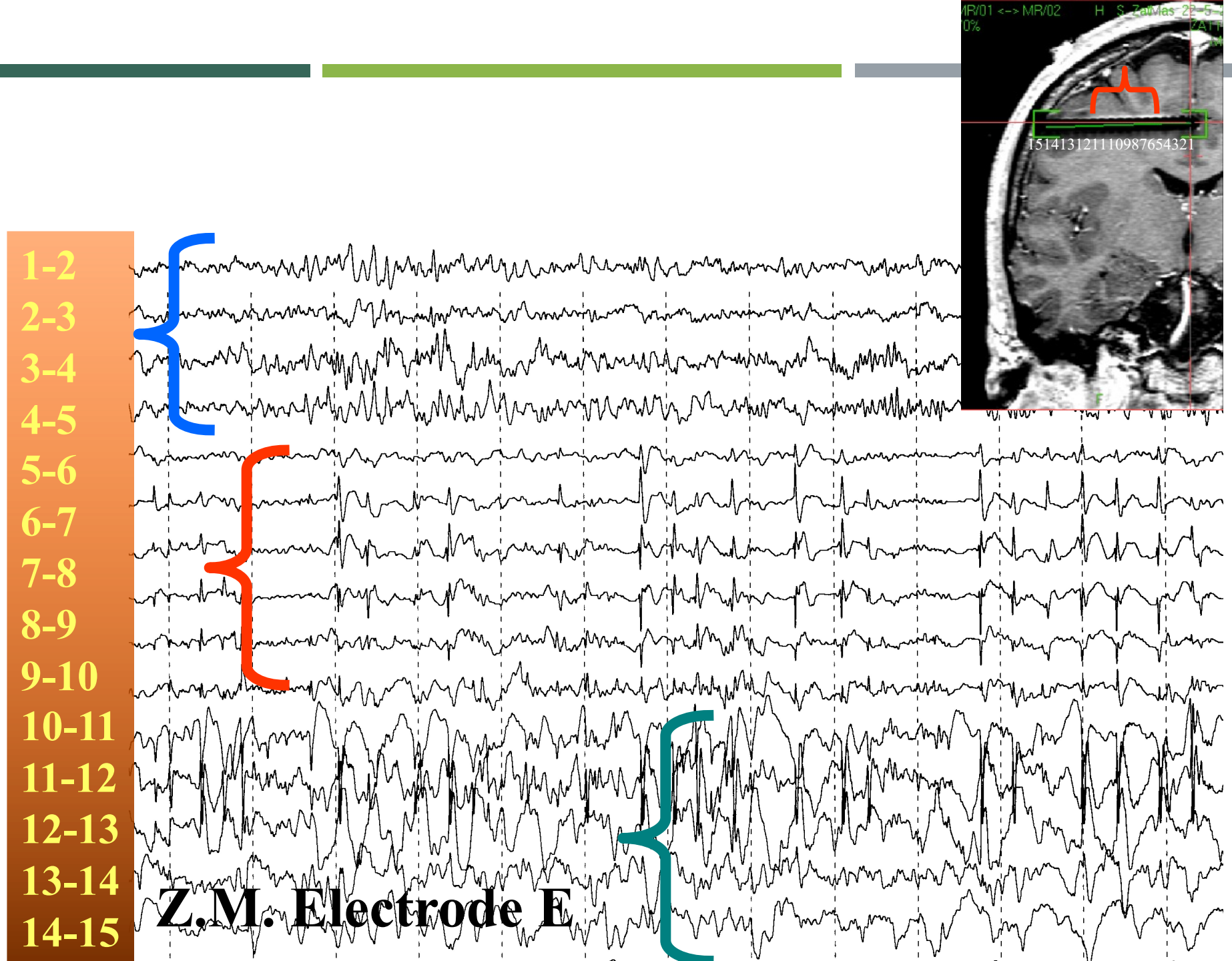
1-2
2-3
3-4
4-5
5-6
6-7
7-8
8-9
9-10
10-11
11-12
12-13
13-14
14-15
Z.M. Electrode E
151413121110987654321

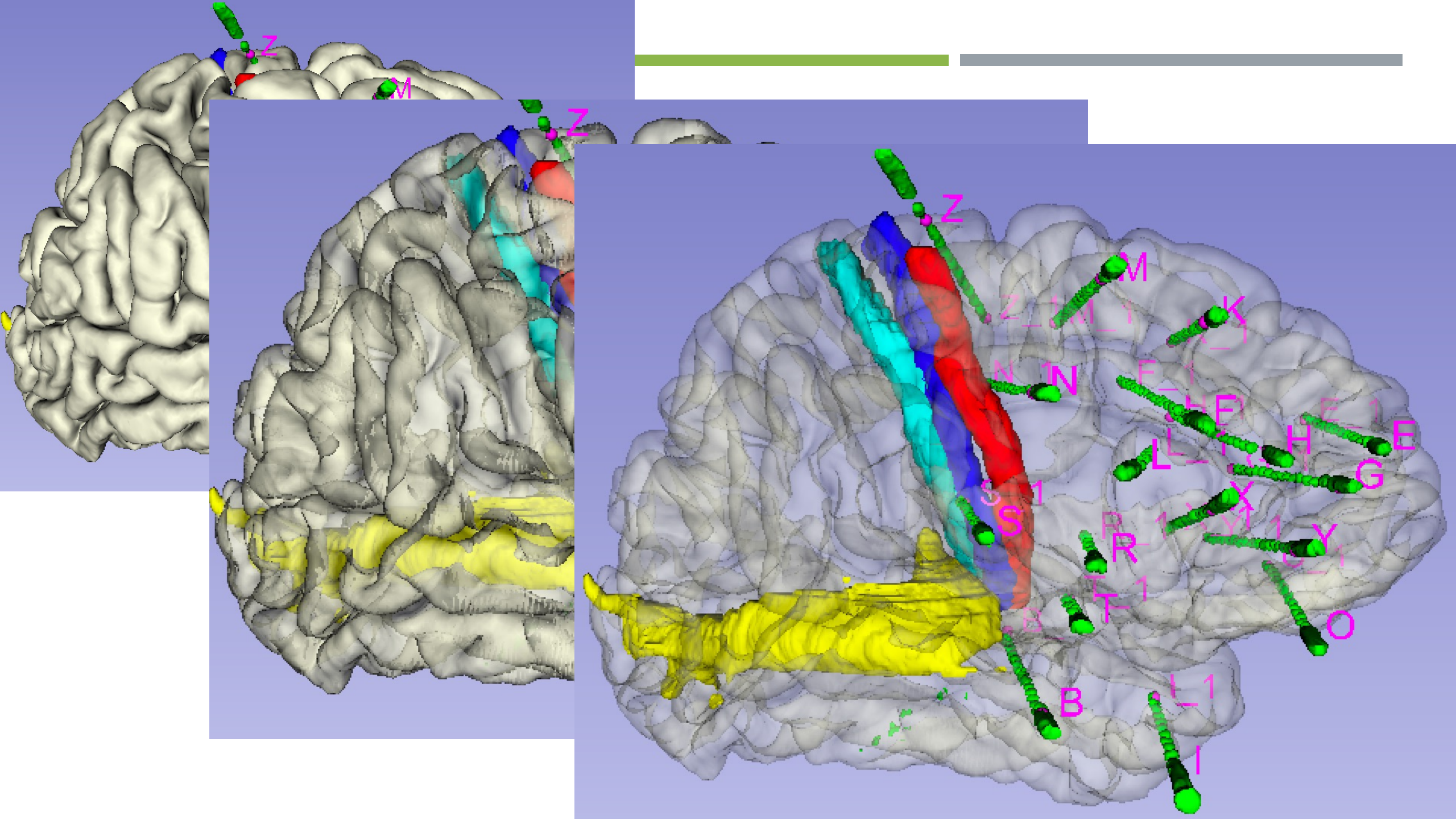
Z
M
Z
Z
M
K
N
F
E
H
L
G
X
Y
R
T
O
B
I

PHYSIOLOGY

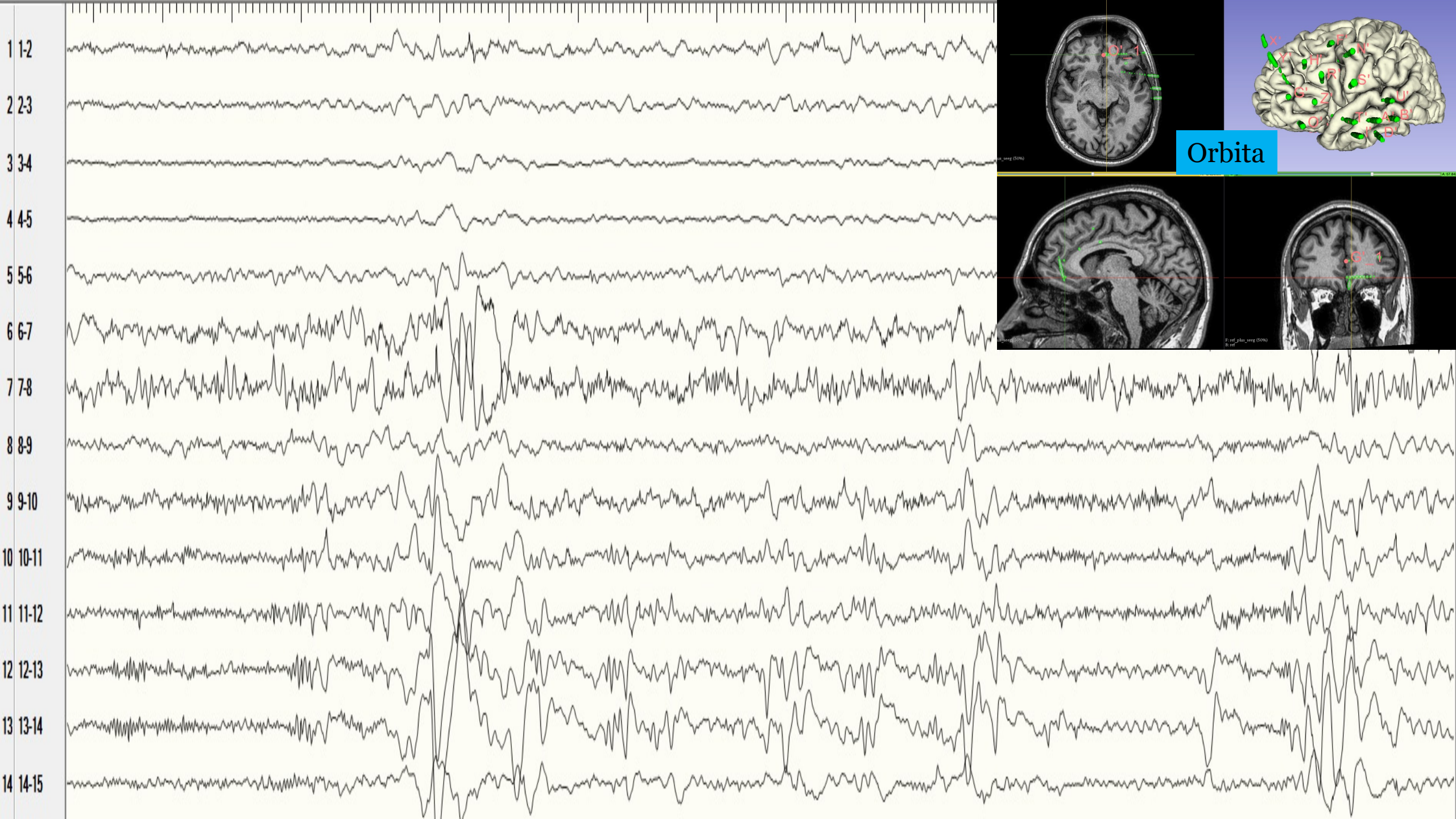
1 1-2
2 2-3
3 3-4
4 4-5
5 5-6
6 6-7
7 7-8
8 8-9
9 9-10
10 10-11
11 11-12
12 12-13
13 13-14
14 14-15
Orbita

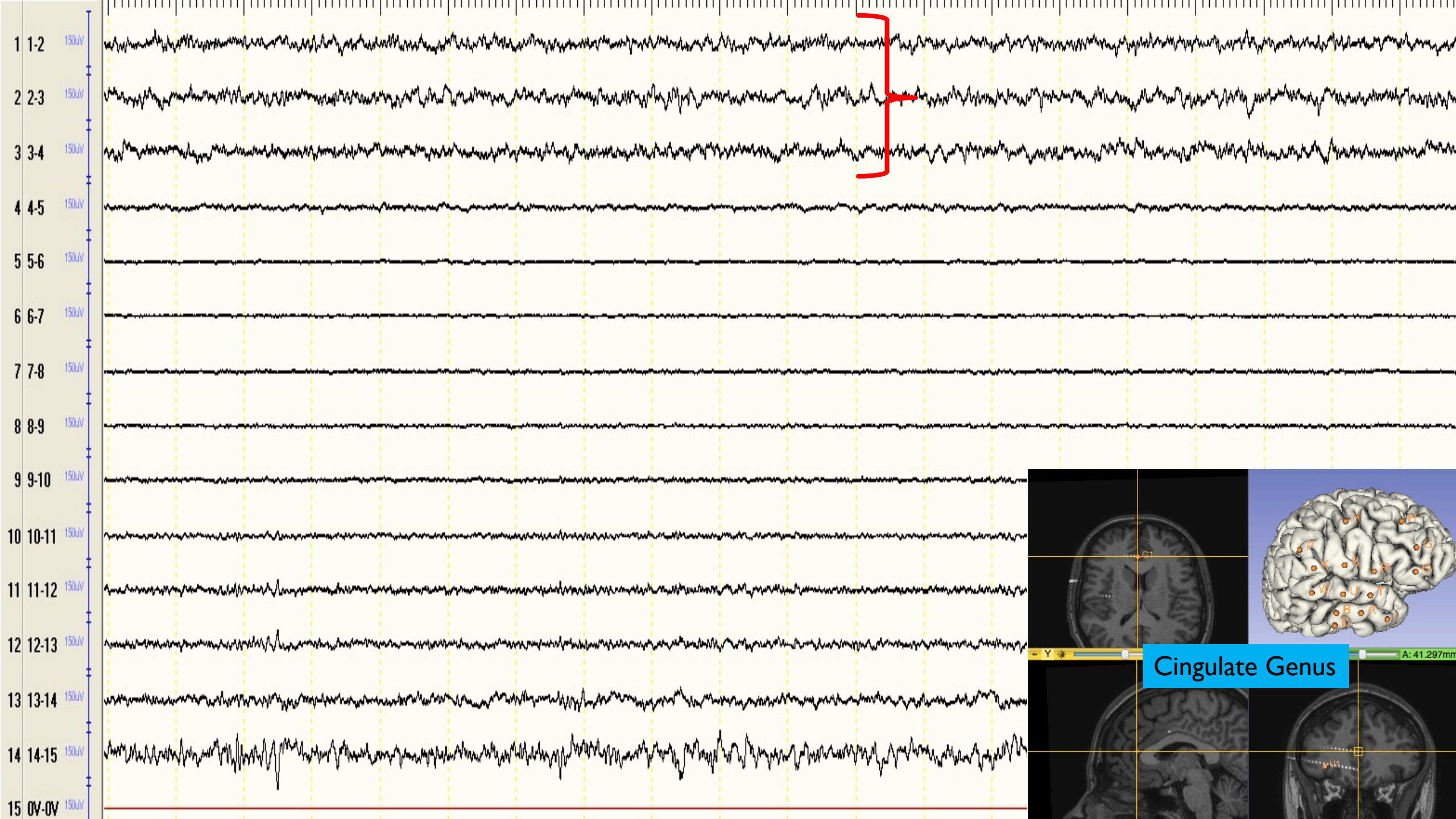
1 1-2 150uV
2 2-3 150uV
3 3-4 150uV
4 4-5 150uV
5 5-6 150uV
6 6-7 150uV
7 7-8 150uV
8 8-9 150uV
9 9-10 150uV
10 10-11 150uV
11 11-12 150uV
12 12-13 150uV
13 13-14 150uV
14 14-15 150uV
15 0V-0V 150uV
Cingulate Genus

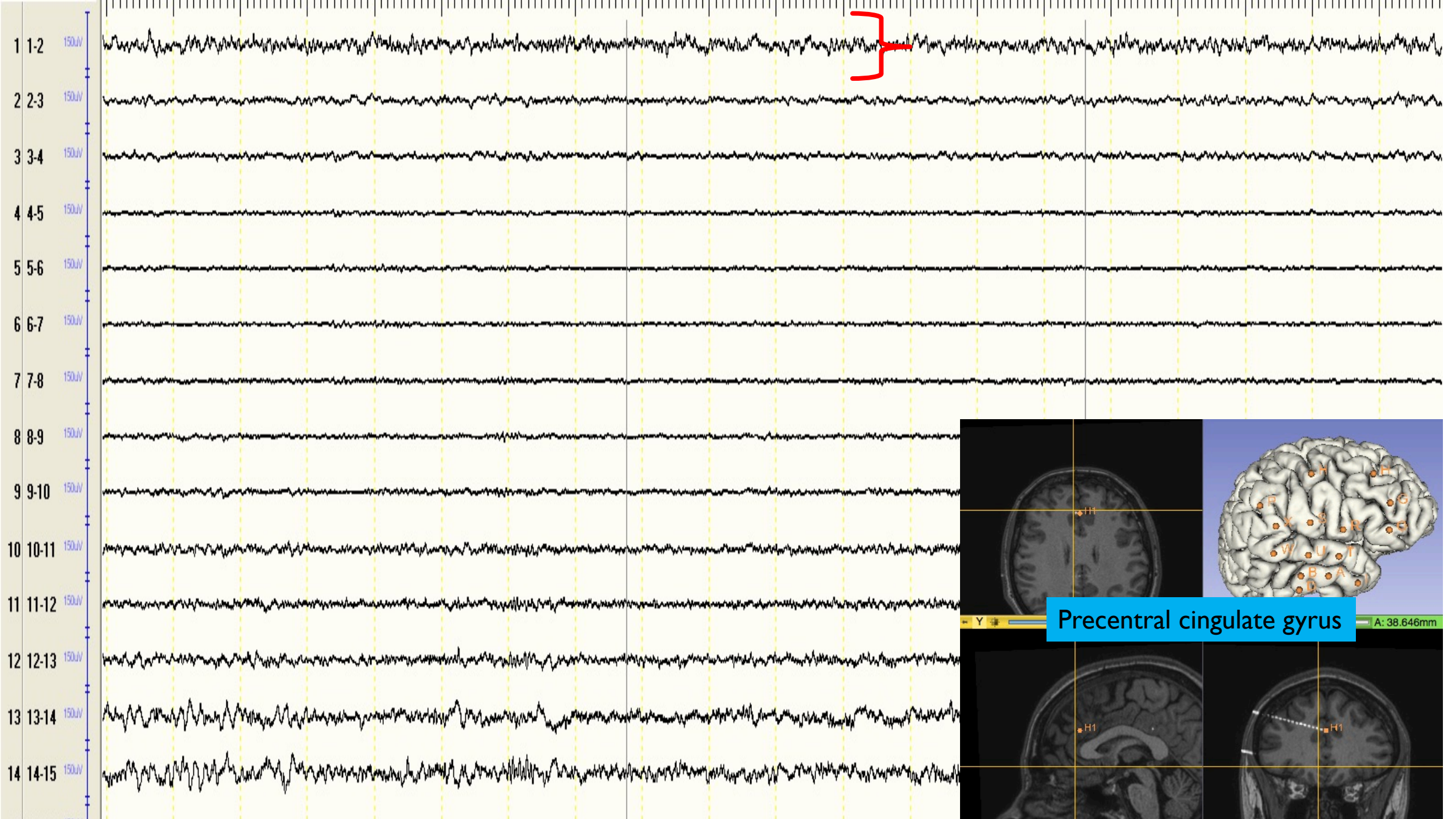
1 1-2 150uV
2 2-3 150uV
3 3-4 150uV
4 4-5 150uV
5 5-6 150uV
6 6-7 150uV
7 7-8 150uV
8 8-9 150uV
9 9-10 150uV
10 10-11 150uV
11 11-12 150uV
12 12-13 150uV
13 13-14 150uV
14 14-15 150uV
Precentral cingulate gyrus
A: 38.646mm

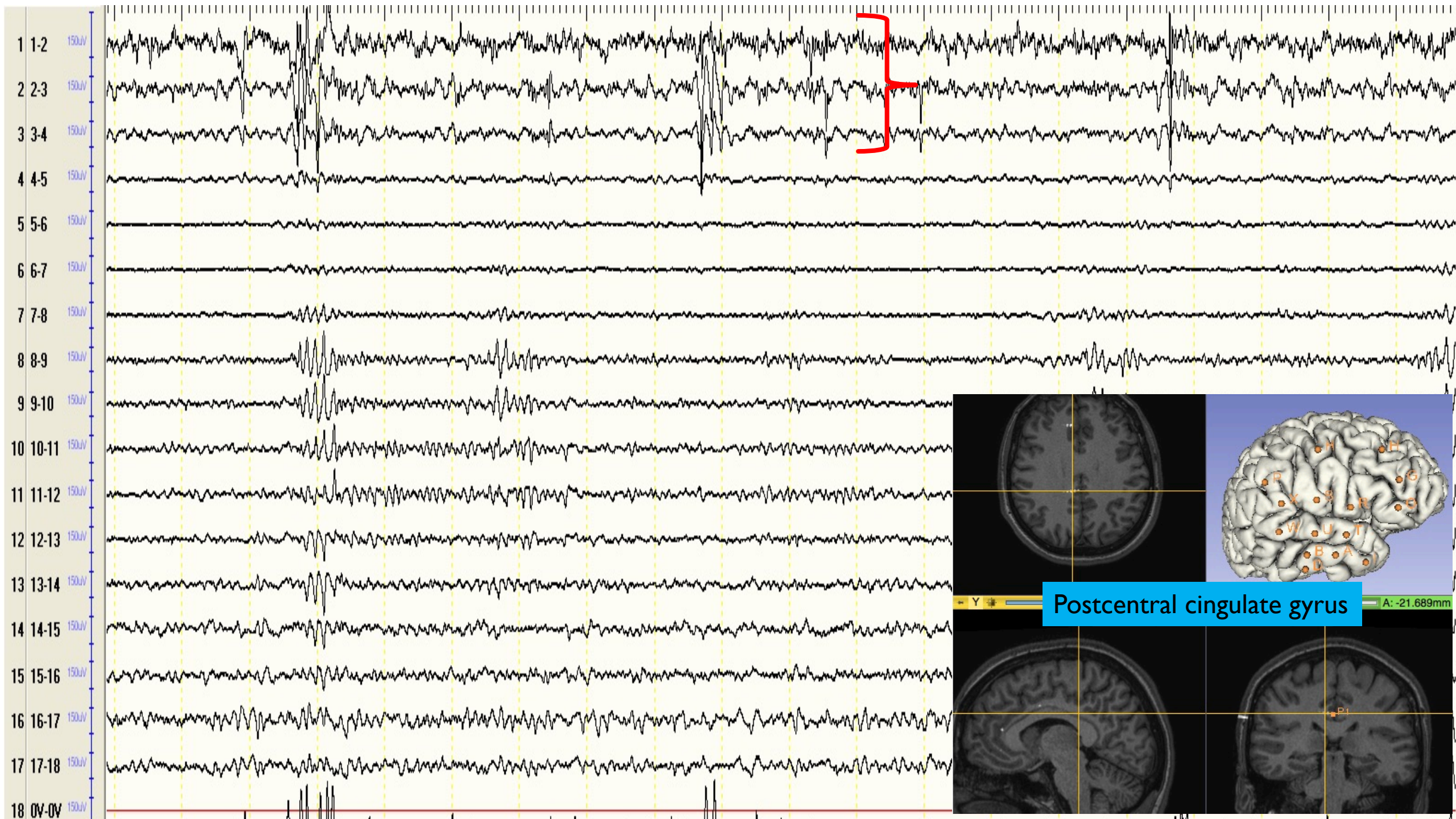
1 1-2
2 2-3
3 3-4
4 4-5
5 5-6
6 6-7
7 7-8
8 8-9
9 9-10
10 10-11
11 11-12
12 12-13
13 13-14
14 14-15
15 15-16
16 16-17
17 17-18
18 0V-0V
150uV
Postcentral cingulate gyrus
A: -21.689mm

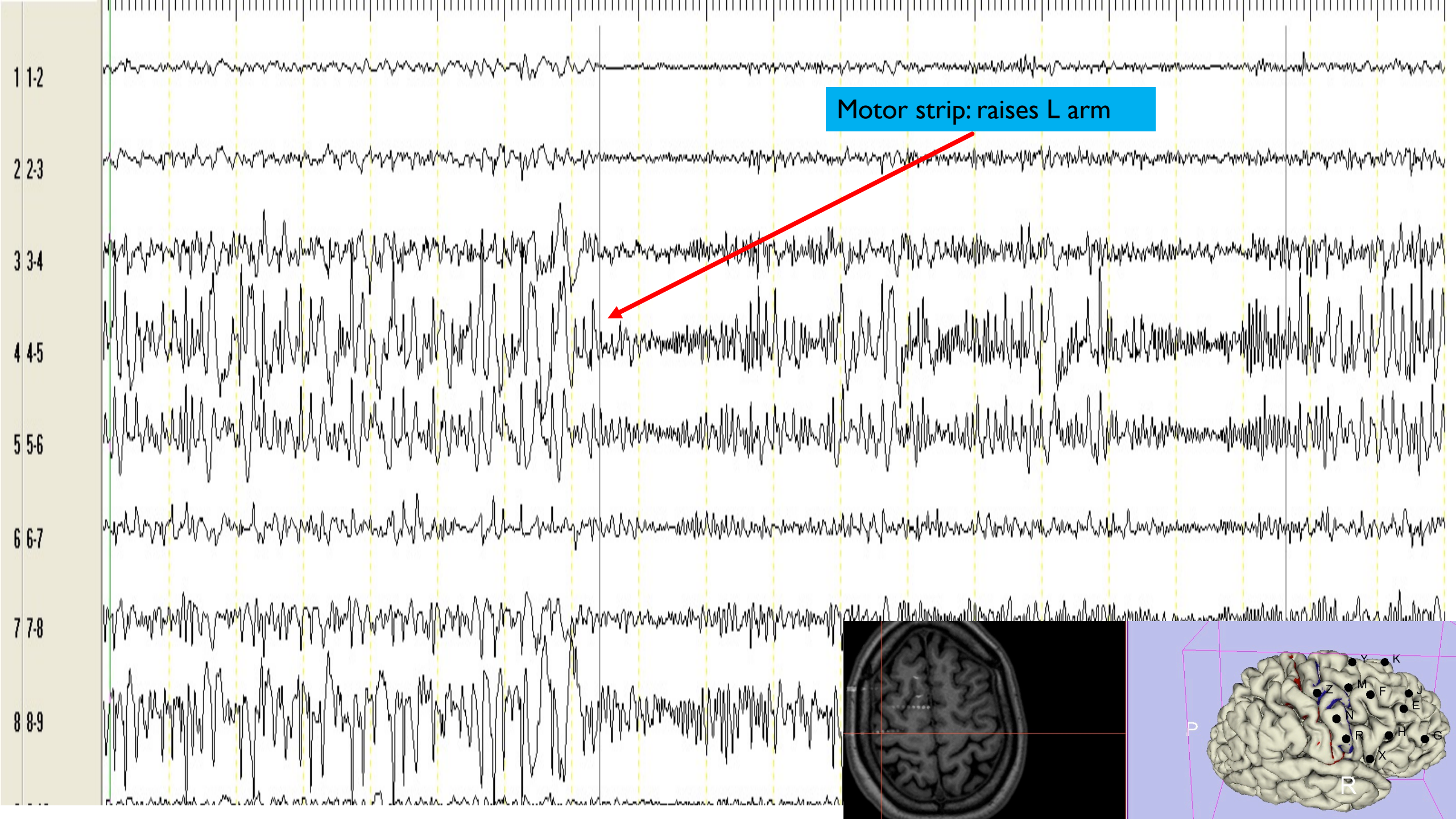
1 1-2
2 2-3
3 3-4
4 4-5
5 5-6
6 6-7
7 7-8
8 8-9
Motor strip: raises L arm
Y
K
Z
M
F
J
E
N
R
H
G
X
R

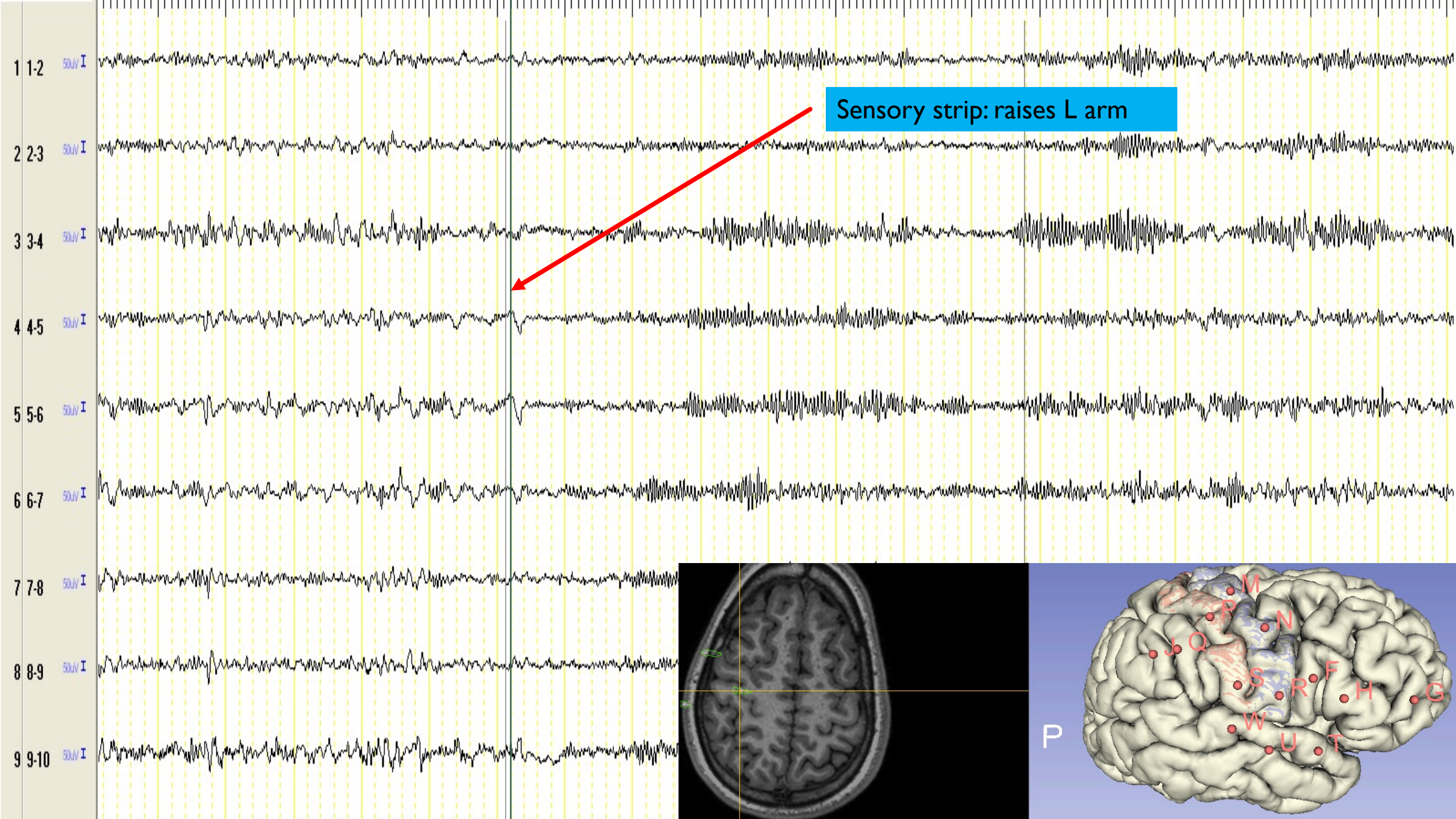
1 1-2
2 2-3
3 3-4
4 4-5
5 5-6
6 6-7
7 7-8
8 8-9
9 9-10
50uV
Sensory strip: raises L arm
M
P
N
J
Q
S
R
F
H
G
W
U
T
P

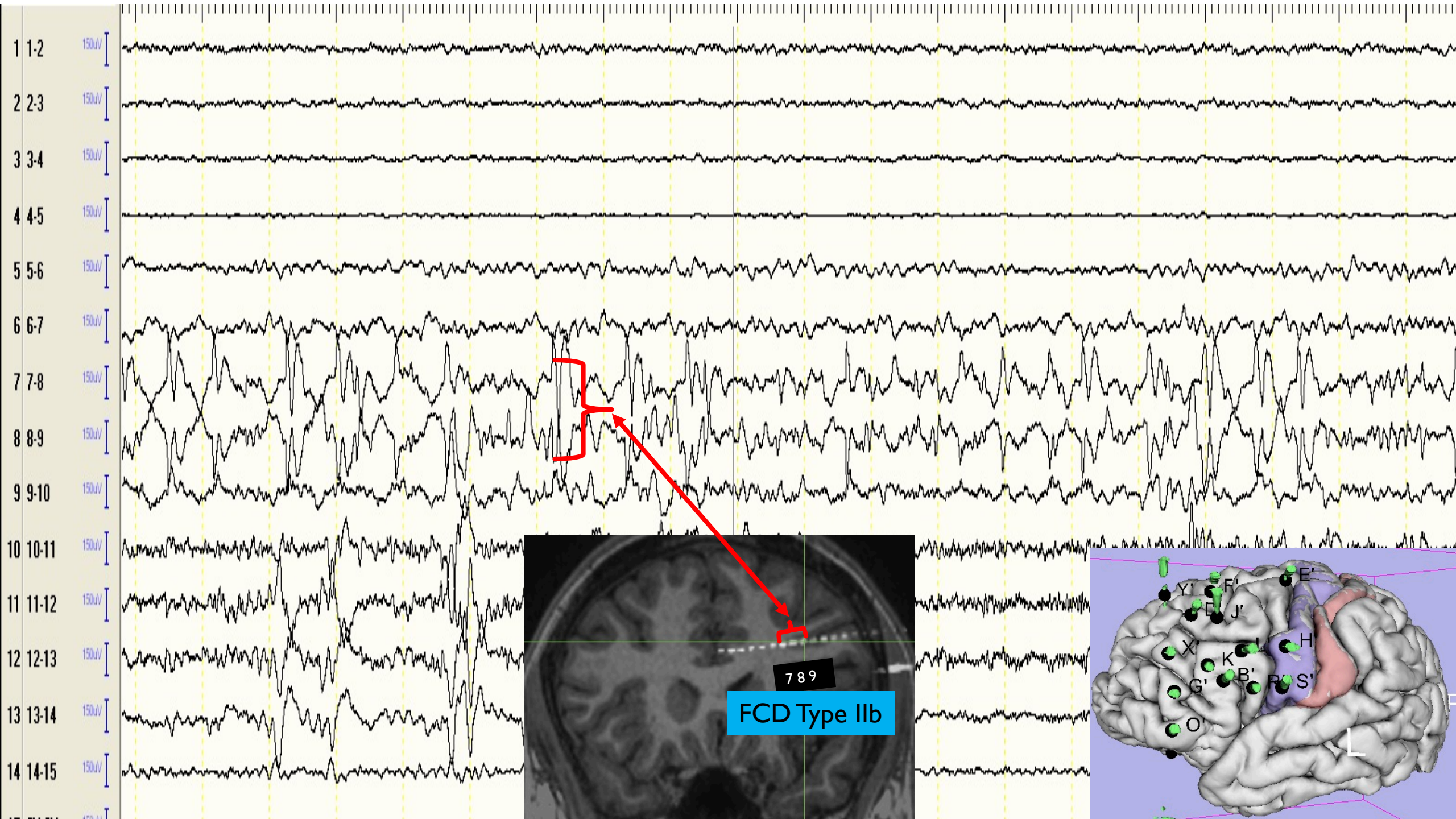
1 1-2
2 2-3
3 3-4
4 4-5
5 5-6
6 6-7
7 7-8
8 8-9
9 9-10
10 10-11
11 11-12
12 12-13
13 13-14
14 14-15
150uV
7 8 9
FCD Type IIb
Y'
F'
E'
D'
J'
X'
K
L'
H'
B'
G'
P'
S'
O'
L

Intracerebral Stimulations

Epilepsy and the functional anatomy of the brain. (Penfield and Jasper, 1954).

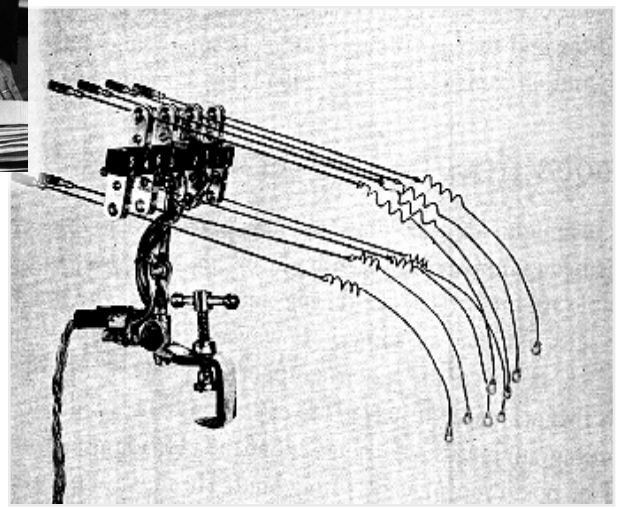

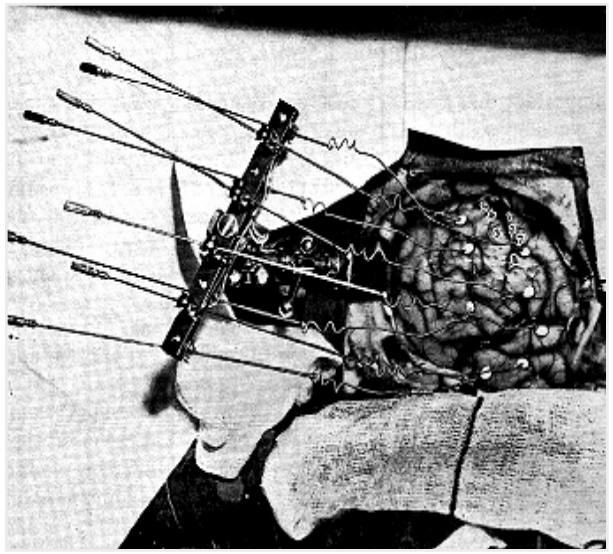

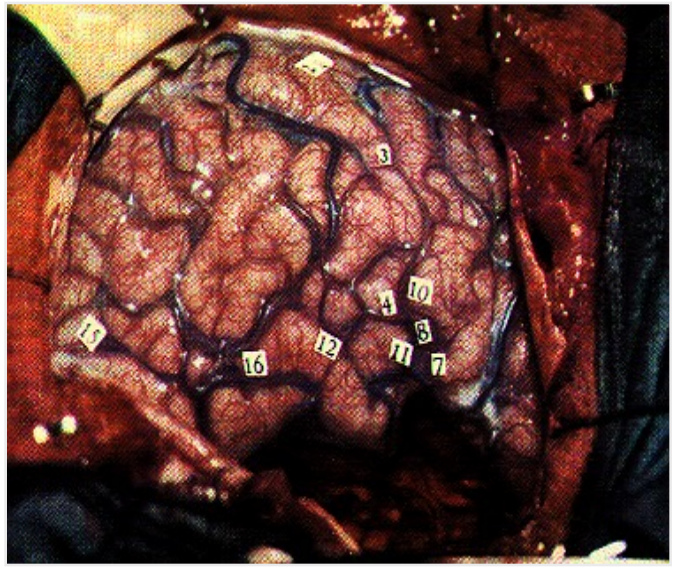

Stereo-EEG in acuto

STIMULATIONS

Low Frequency

- ✓ Frequency: 1-18 Hz
- ✓ Pulse duration: 3 msec
- ✓ Intensity: 0.1 - 10 mA
- ✓ Mean duration 30-40 sec.

Neurophysiologcal mapping
Seizures

High Frequency

- ✓ Frequency: 50 Hz
- ✓ Pulse Duration: 1 msec
- ✓ Intensity : 0.5 - 3 mA
- ✓ Mean duration: 5 sec.

Neurophysiologal mapping
Seizures

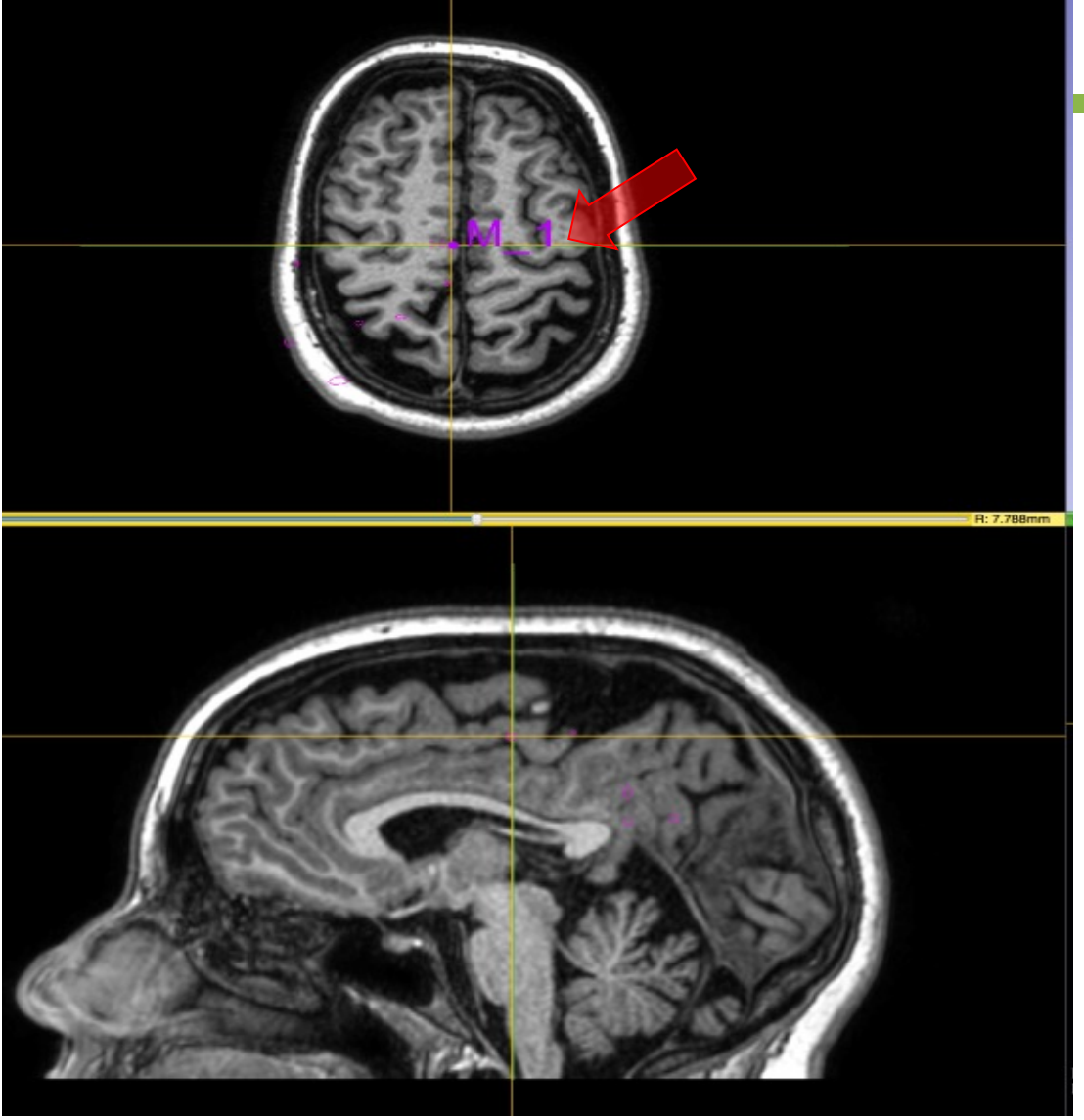

M9-10 1 mA

M9-10 2 mA

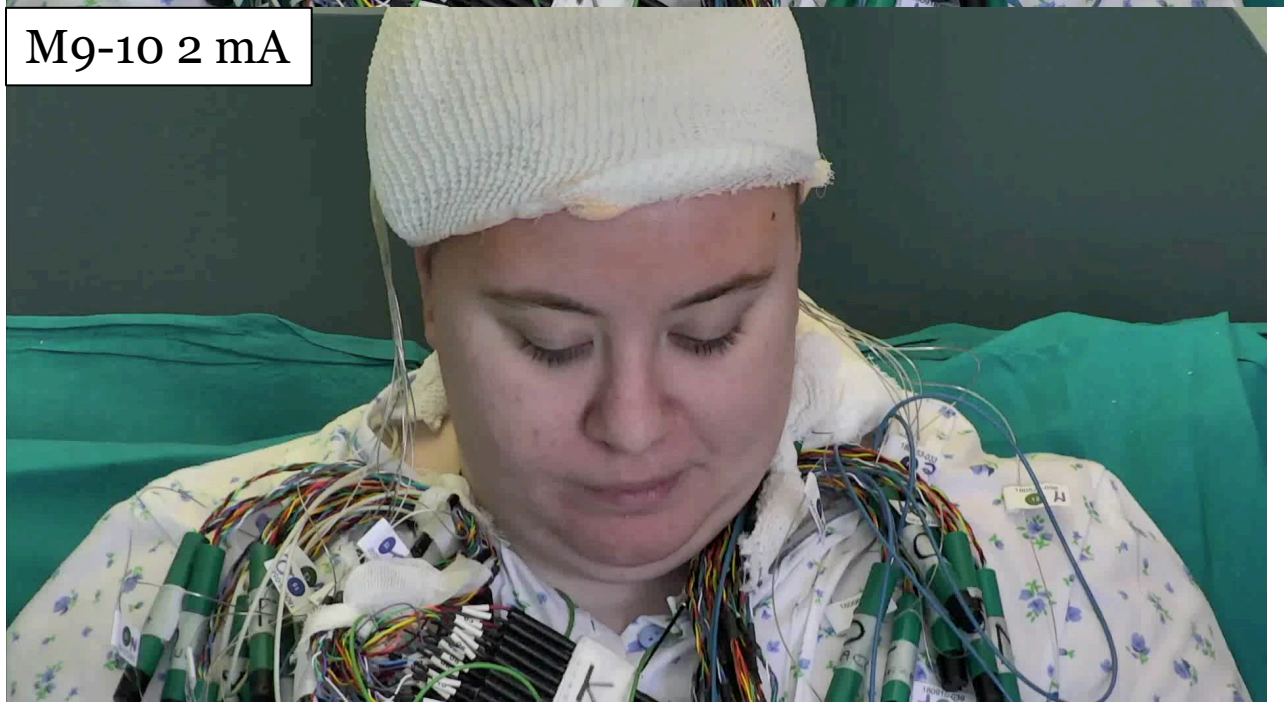

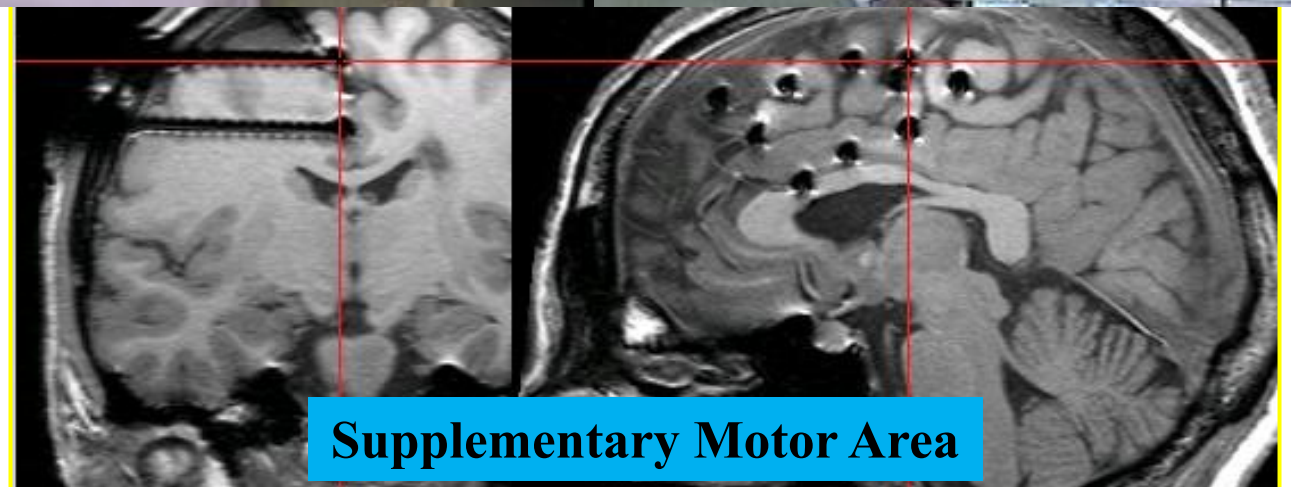
Supplementary Motor Area

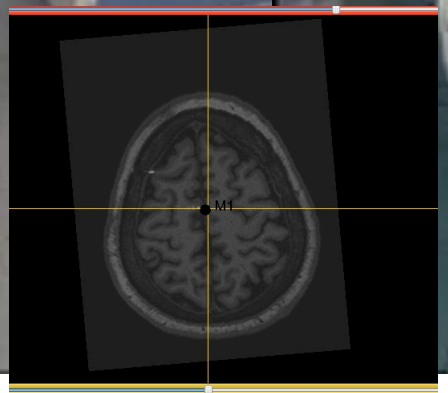

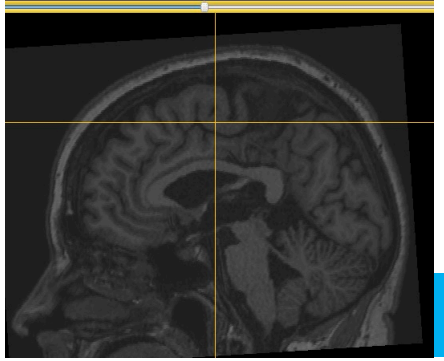

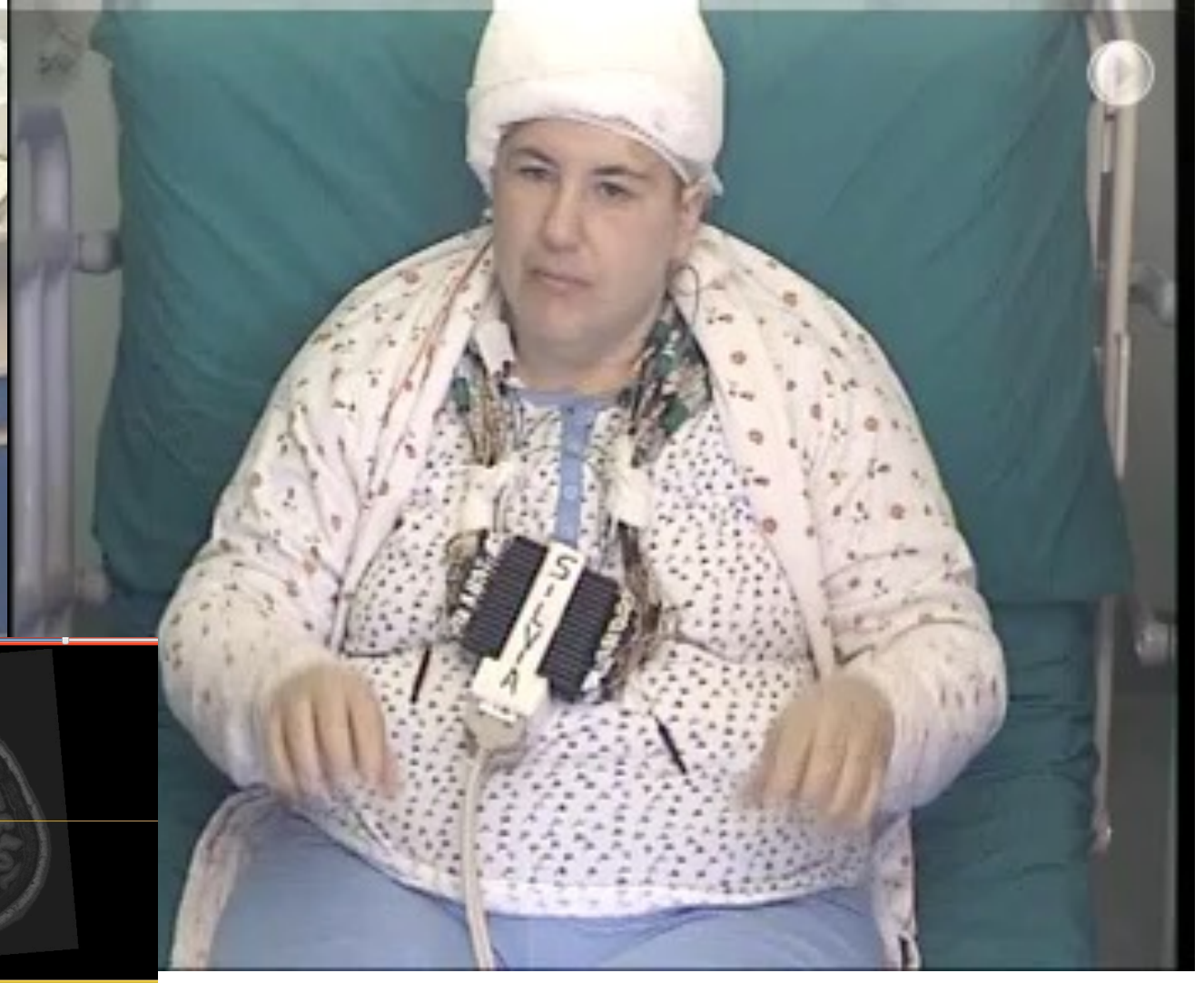

Supplementary Motor Area

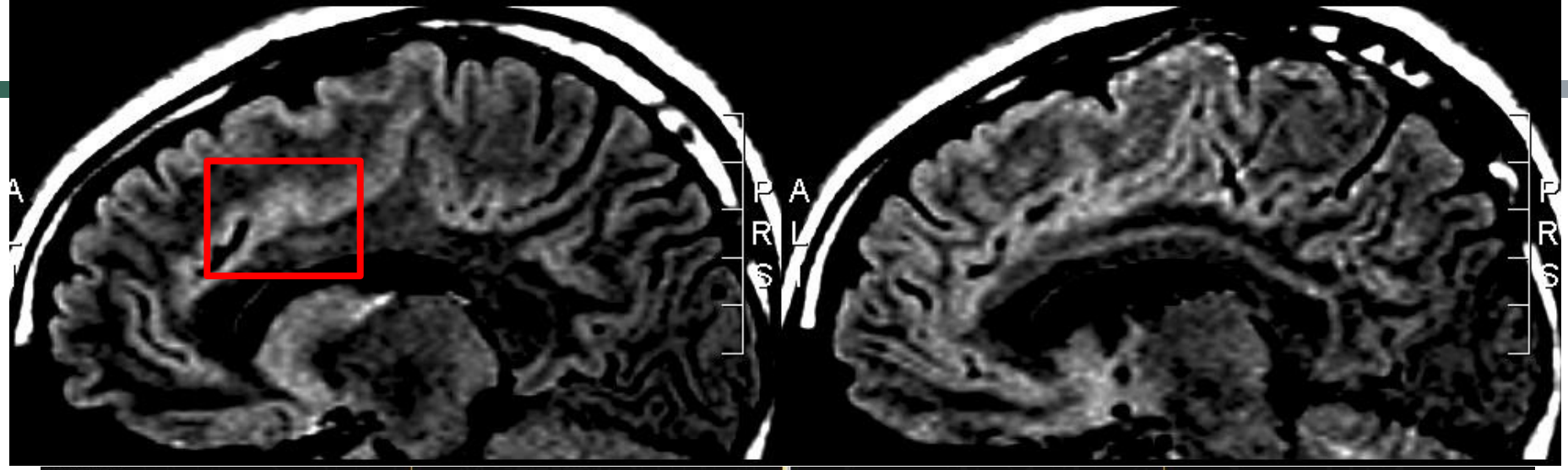
A
P
R
S
A
L
P
R
S

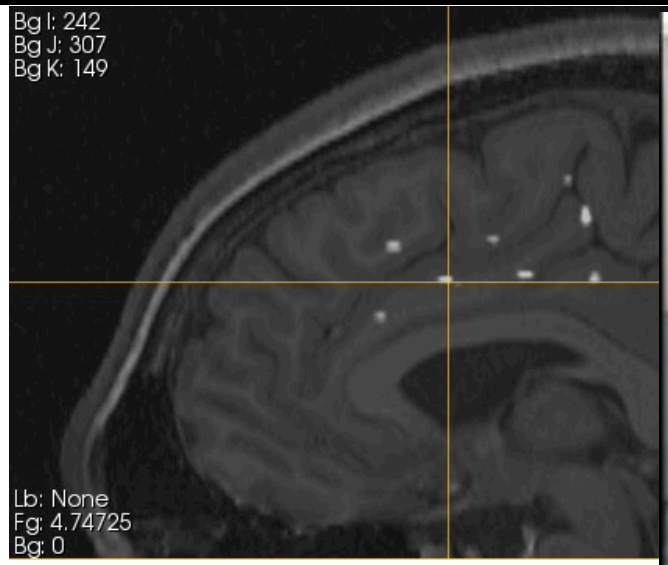
Bg I: 242
Bg J: 307
Bg K: 149
Lb: None
Fg: 4.74725
Bg: 0

Anterior cingulate

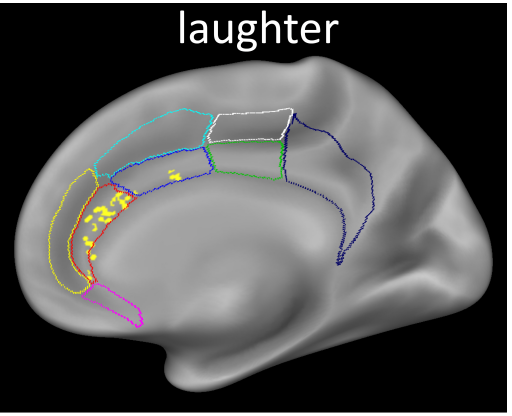

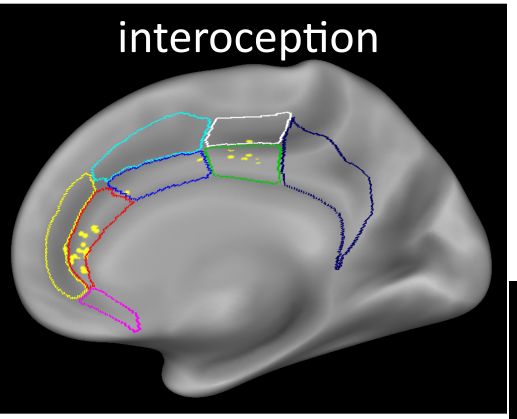

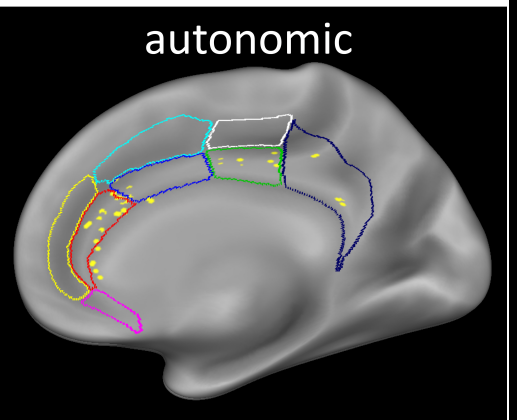

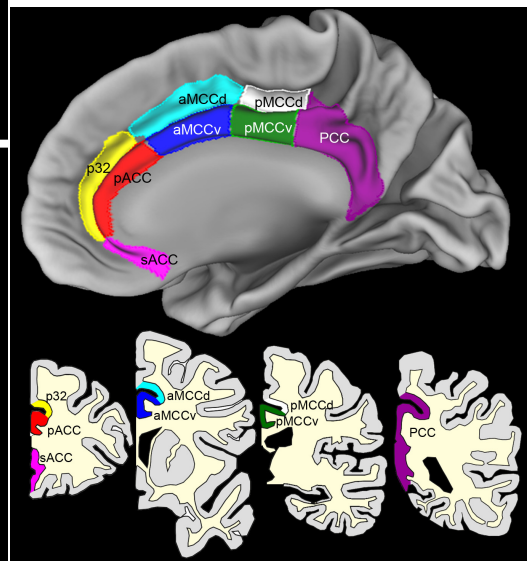

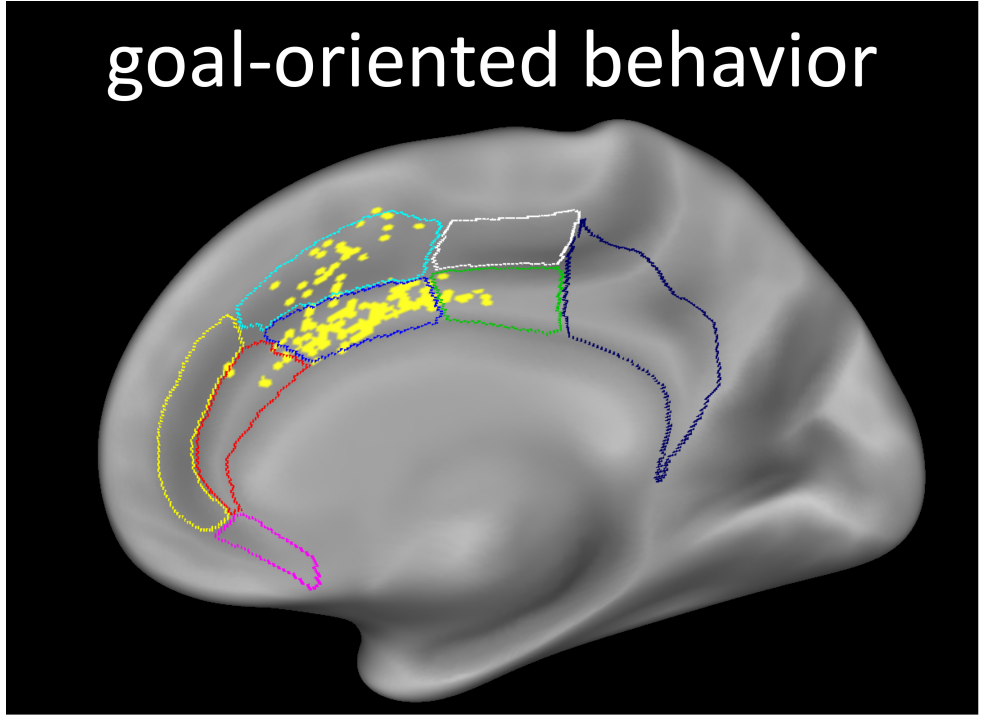

1

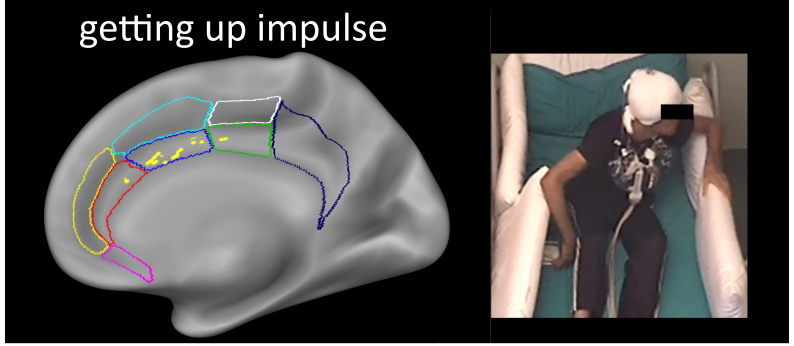

2

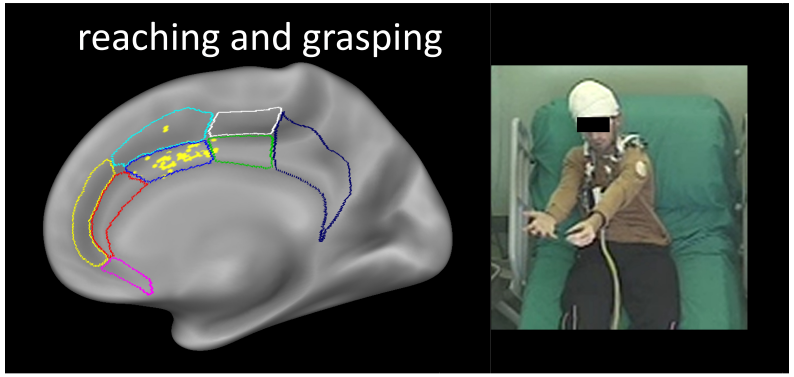

3

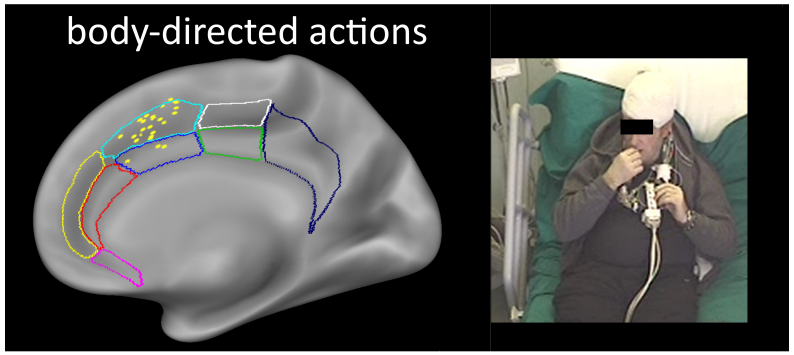

4

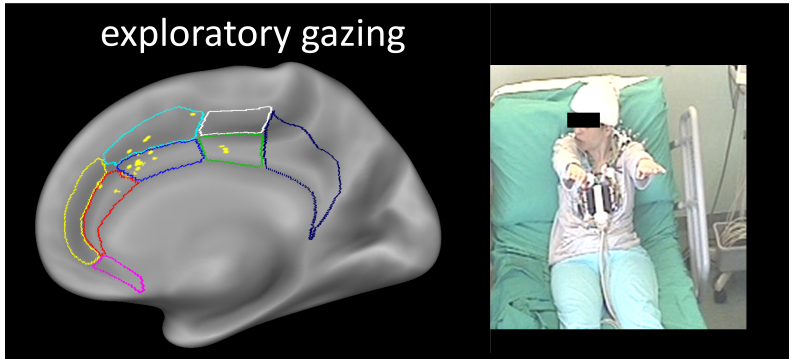

MID CINGULATE

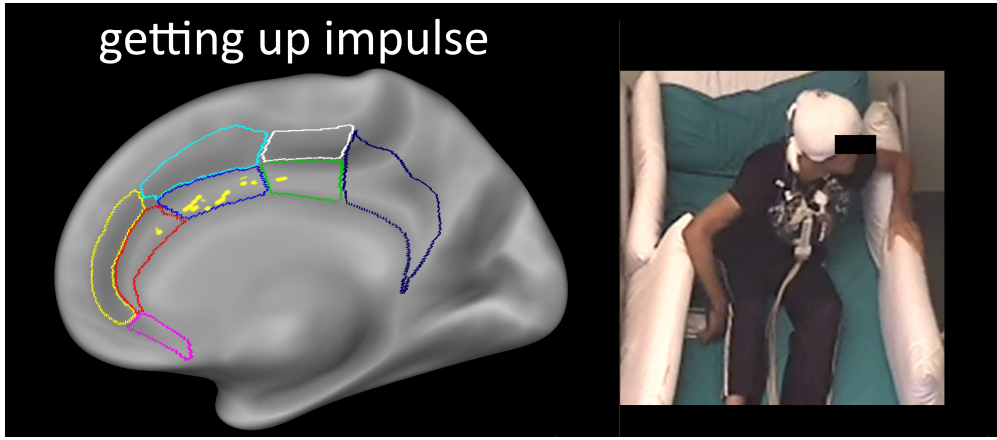

MID CINGULATE

Ictal semeiology

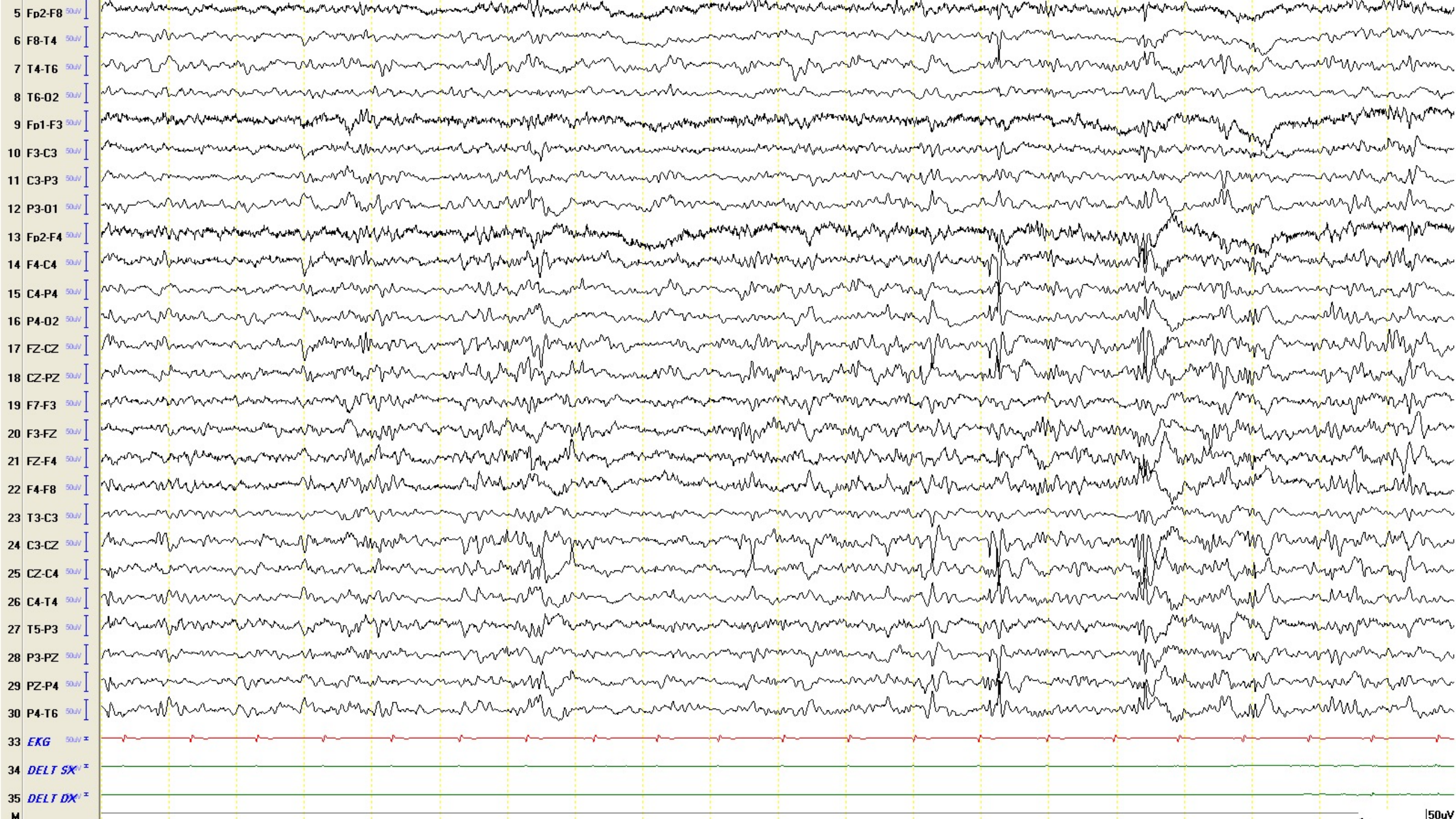
5 Fp2-F8 50uV
6 F8-T4 50uV
7 T4-T6 50uV
8 T6-O2 50uV
9 Fp1-F3 50uV
10 F3-C3 50uV
11 C3-P3 50uV
12 P3-O1 50uV
13 Fp2-F4 50uV
14 F4-C4 50uV
15 C4-P4 50uV
16 P4-O2 50uV
17 FZ-CZ 50uV
18 CZ-PZ 50uV
19 F7-F3 50uV
20 F3-FZ 50uV
21 FZ-F4 50uV
22 F4-F8 50uV
23 T3-C3 50uV
24 C3-CZ 50uV
25 CZ-C4 50uV
26 C4-T4 50uV
27 T5-P3 50uV
28 P3-PZ 50uV
29 PZ-P4 50uV
30 P4-T6 50uV
33 EKG 50uV
34 DELT SX
35 DELT DX
50uV

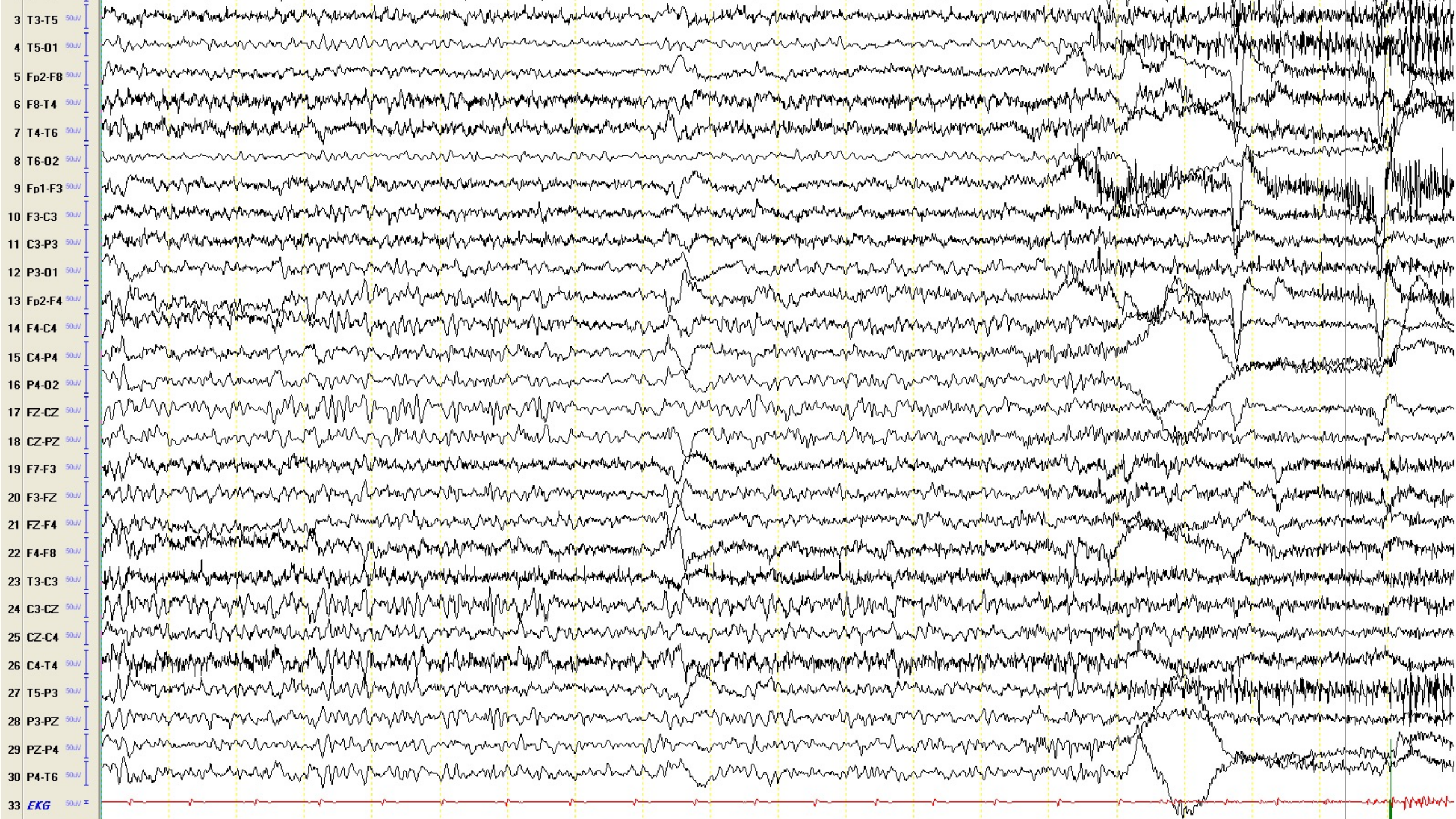
3 T3-T5 50uV
4 T5-O1 50uV
5 Fp2-F8 50uV
6 F8-T4 50uV
7 T4-T6 50uV
8 T6-O2 50uV
9 Fp1-F3 50uV
10 F3-C3 50uV
11 C3-P3 50uV
12 P3-O1 50uV
13 Fp2-F4 50uV
14 F4-C4 50uV
15 C4-P4 50uV
16 P4-O2 50uV
17 FZ-CZ 50uV
18 CZ-PZ 50uV
19 F7-F3 50uV
20 F3-FZ 50uV
21 FZ-F4 50uV
22 F4-F8 50uV
23 T3-C3 50uV
24 C3-CZ 50uV
25 CZ-C4 50uV
26 C4-T4 50uV
27 T5-P3 50uV
28 P3-PZ 50uV
29 PZ-P4 50uV
30 P4-T6 50uV
33 EKG 50uV

1 G2-G3
2 G7-G8
3 G10-G11
4 J1-J2
5 J5-J6
6 E2-E3
7 E5-E6
8 E9-E10
9 H1-H2
10 H8-H9
11 H10-H11
12 H12-H13
13 K1-K2
14 K5-K6
15 Y2-Y3
16 Y4-Y5
17 Y7-Y8
18 F1-F2
19 F5-F6
20 F9-F10
21 *M1-M2*
22 M4-M5
23 M8-M9
24 Z1-Z2
25 Z5-Z6
26 Z8-Z9
27 N1-N2
28 N9-N10
29 N13-N14
30 R2-R3
31 R5-R6
32 R8-R9
33 X2-X3
34 X5-X6
35 X6-X7
36 *EKG*
37 *DEL SX*
38 *DEL DX*
M

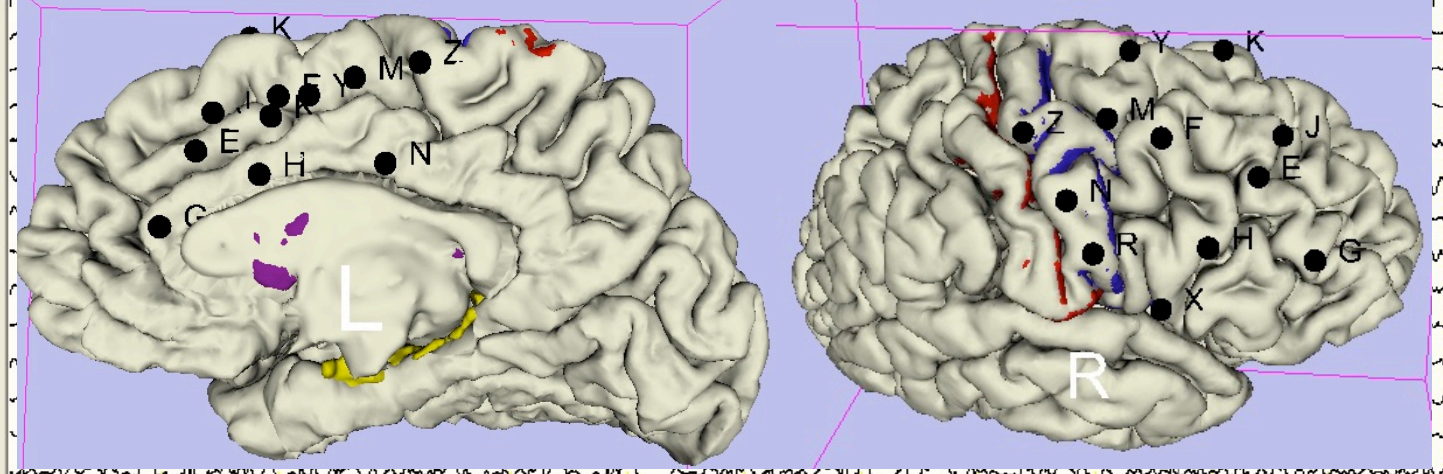

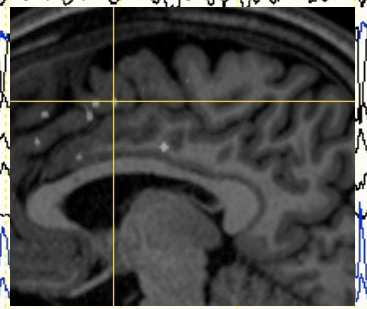

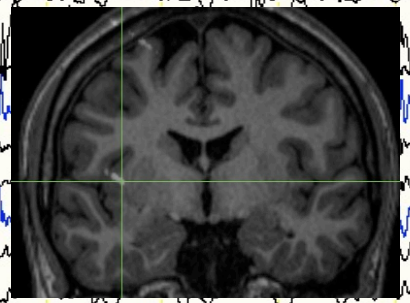

Crisi

Treno M3-4 a 2 mA

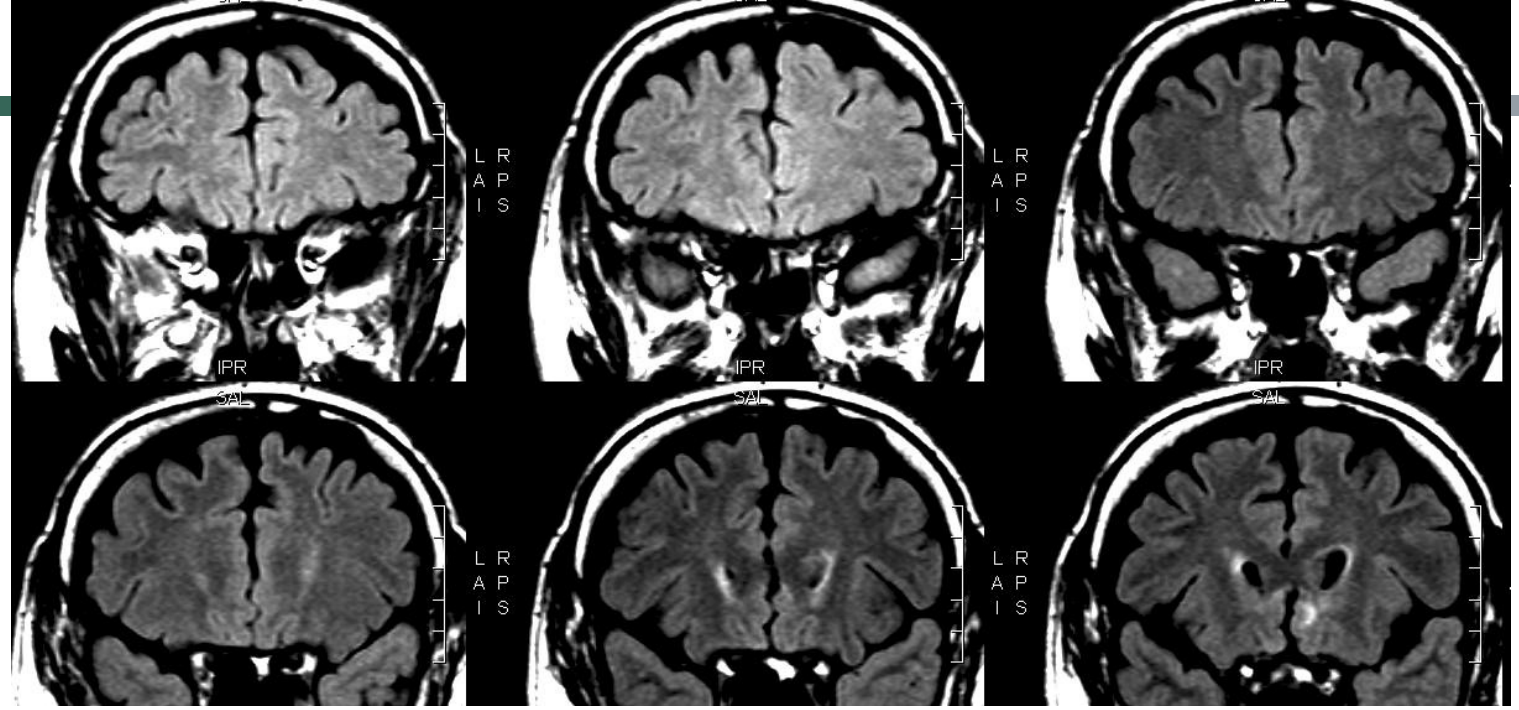
IPR
SAL
L R
A P
I S

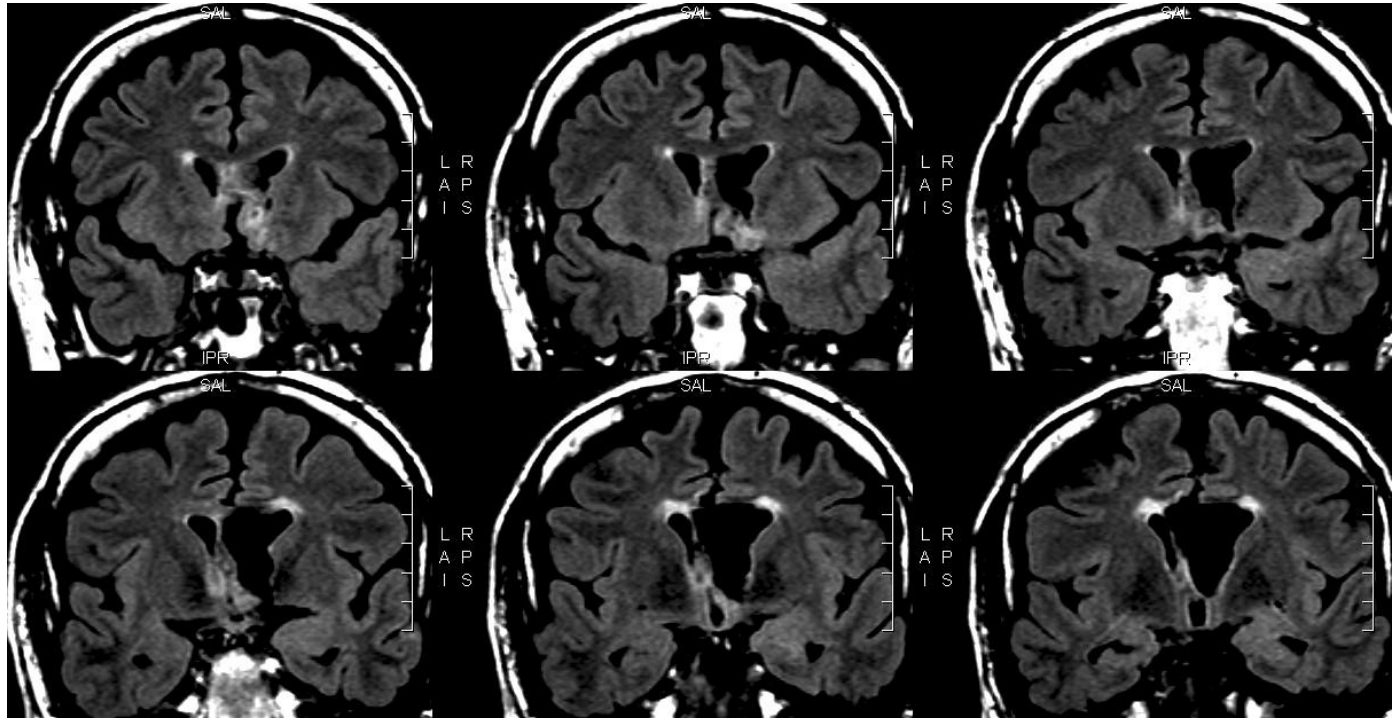
SAL
IPR
L R
A P
I S

CRISI 16.00.58 A

B

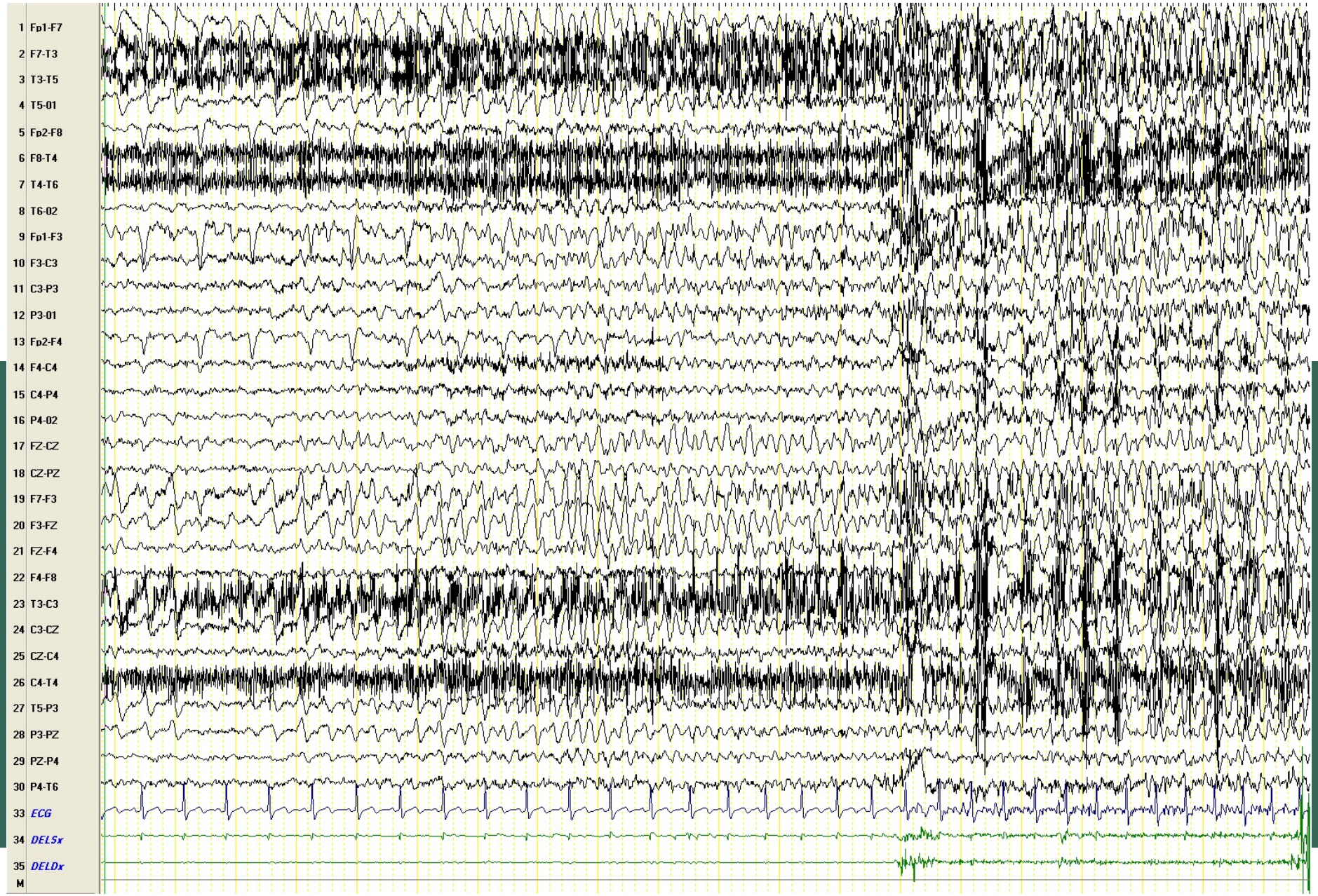
1 Fp1-F7
2 F7-T3
3 T3-T5
4 T5-01
5 Fp2-F8
6 F8-T4
7 T4-T6
8 T6-02
9 Fp1-F3
10 F3-C3
11 C3-P3
12 P3-01
13 Fp2-F4
14 F4-C4
15 C4-P4
16 P4-02
17 FZ-CZ
18 CZ-PZ
19 F7-F3
20 F3-FZ
21 FZ-F4
22 F4-F8
23 T3-C3
24 C3-CZ
25 CZ-C4
26 C4-T4
27 T5-P3
28 P3-PZ
29 PZ-P4
30 P4-T6
33 ECG
34 DELSx
35 DELDx
M

C

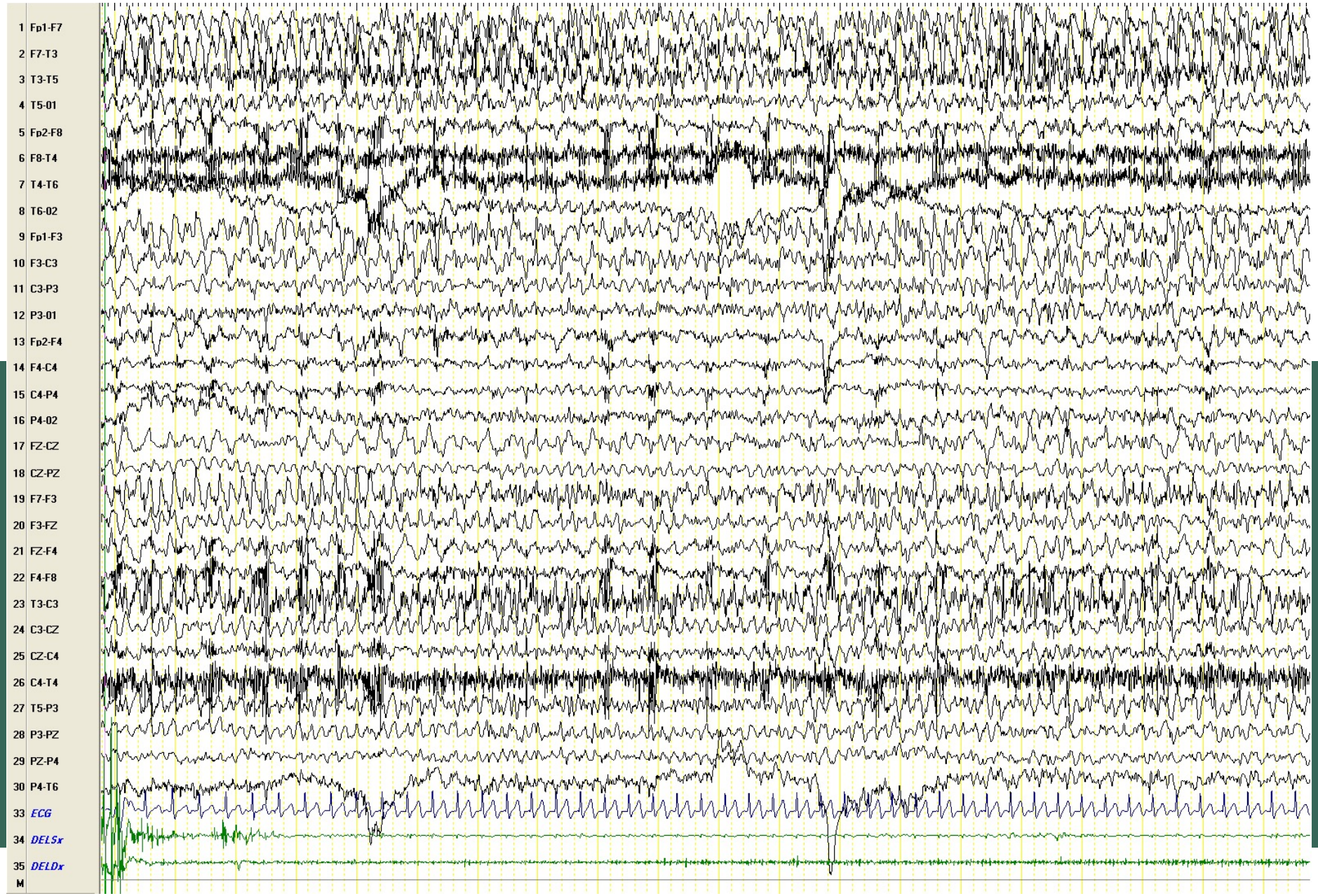
1 Fp1-F7
2 F7-T3
3 T3-T5
4 T5-01
5 Fp2-F8
6 F8-T4
7 T4-T6
8 T6-02
9 Fp1-F3
10 F3-C3
11 C3-P3
12 P3-01
13 Fp2-F4
14 F4-C4
15 C4-P4
16 P4-02
17 FZ-CZ
18 CZ-PZ
19 F7-F3
20 F3-FZ
21 FZ-F4
22 F4-F8
23 T3-C3
24 C3-CZ
25 CZ-C4
26 C4-T4
27 T5-P3
28 P3-PZ
29 PZ-P4
30 P4-T6
33 ECG
34 DELSx
35 DELDx
M

D

1 Fp1-F7
2 F7-T3
3 T3-T5
4 T5-01
5 Fp2-F8
6 F8-T4
7 T4-T6
8 T6-02
9 Fp1-F3
10 F3-C3
11 C3-P3
12 P3-01
13 Fp2-F4
14 F4-C4
15 C4-P4
16 P4-02
17 FZ-CZ
18 CZ-PZ
19 F7-F3
20 F3-FZ
21 FZ-F4
22 F4-F8
23 T3-C3
24 C3-CZ
25 CZ-C4
26 C4-T4
27 T5-P3
28 P3-PZ
29 PZ-P4
30 P4-T6
33 ECG
34 DELSx
35 DELDx
M

E

1 Fp1-F7
2 F7-T3
3 T3-T5
4 T5-01
5 Fp2-F8
6 F8-T4
7 T4-T6
8 T6-02
9 Fp1-F3
10 F3-C3
11 C3-P3
12 P3-01
13 Fp2-F4
14 F4-C4
15 C4-P4
16 P4-02
17 FZ-CZ
18 CZ-PZ
19 F7-F3
20 F3-FZ
21 FZ-F4
22 F4-F8
23 T3-C3
24 C3-CZ
25 CZ-C4
26 C4-T4
27 T5-P3
28 P3-PZ
29 PZ-P4
30 P4-T6
33 ECG
34 DELSx
35 DELDx
M

F

1 Fp1-F7
2 F7-T3
3 T3-T5
4 T5-01
5 Fp2-F8
6 F8-T4
7 T4-T6
8 T6-02
9 Fp1-F3
10 F3-C3
11 C3-P3
12 P3-01
13 Fp2-F4
14 F4-C4
15 C4-P4
16 P4-02
17 FZ-CZ
18 CZ-PZ
19 F7-F3
20 F3-FZ
21 FZ-F4
22 F4-F8
23 T3-C3
24 C3-CZ
25 CZ-C4
26 C4-T4
27 T5-P3
28 P3-PZ
29 PZ-P4
30 P4-T6
33 ECG
34 DELSx
35 DELDx
M

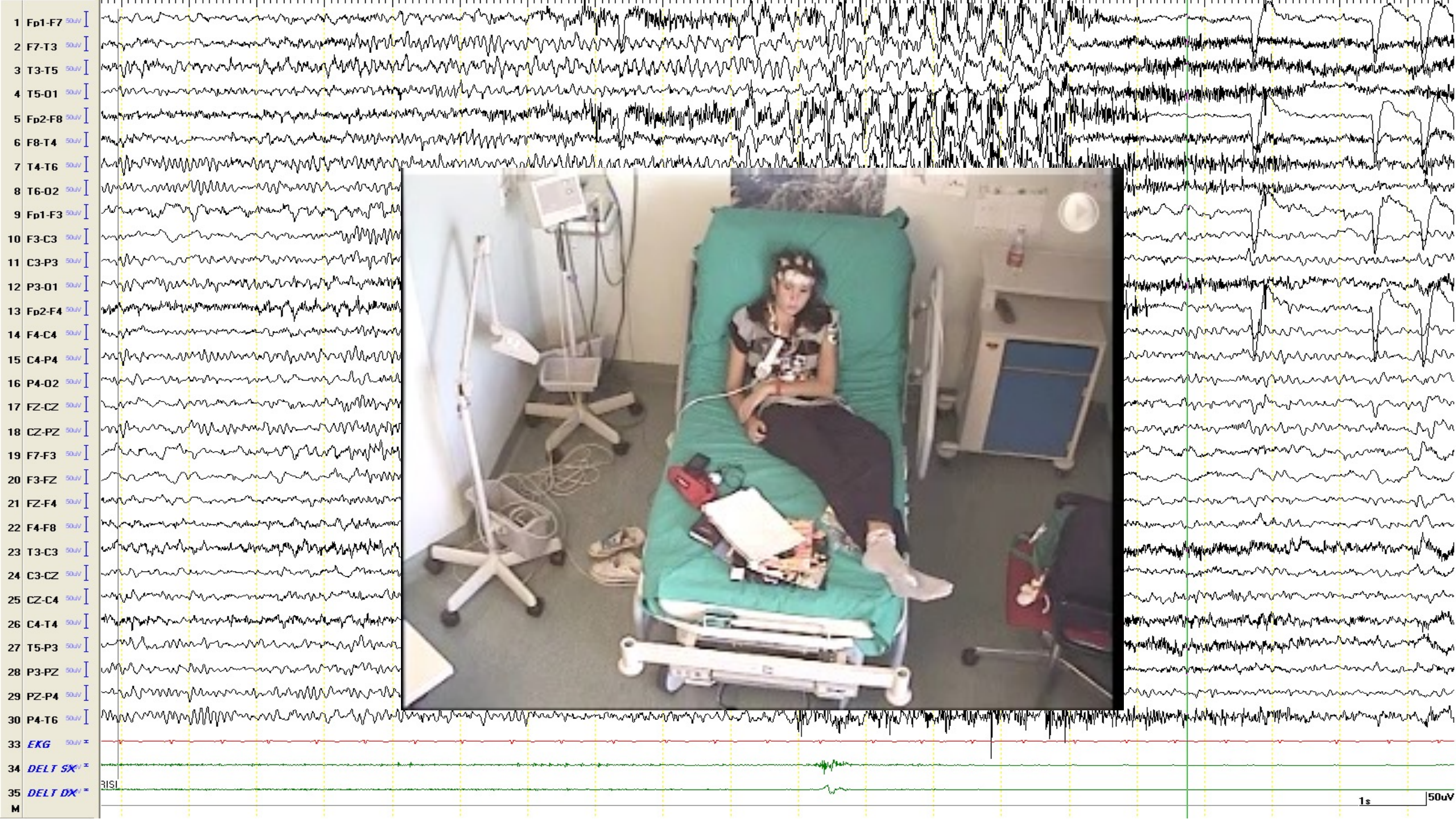
1 Fp1-F7
2 F7-T3
3 T3-T5
4 T5-O1
5 Fp2-F8
6 F8-T4
7 T4-T6
8 T6-O2
9 Fp1-F3
10 F3-C3
11 C3-P3
12 P3-O1
13 Fp2-F4
14 F4-C4
15 C4-P4
16 P4-O2
17 FZ-CZ
18 CZ-PZ
19 F7-F3
20 F3-FZ
21 FZ-F4
22 F4-F8
23 T3-C3
24 C3-CZ
25 CZ-C4
26 C4-T4
27 T5-P3
28 P3-PZ
29 PZ-P4
30 P4-T6
33 EKG
34 DELT SX
35 DELT DX
M
1s
50uV

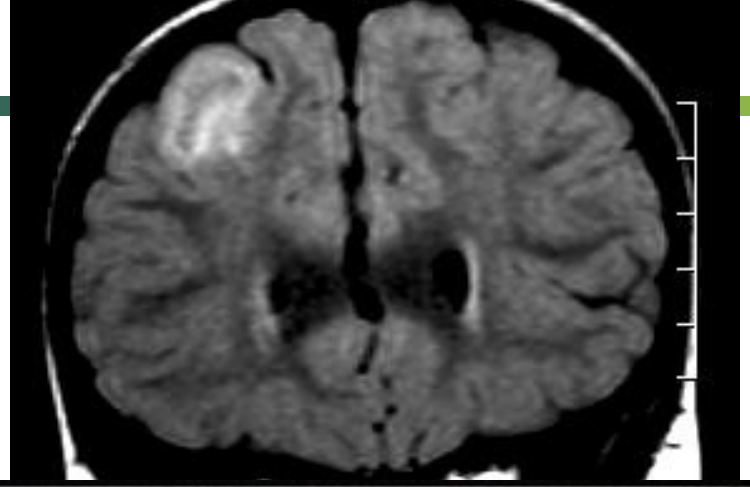

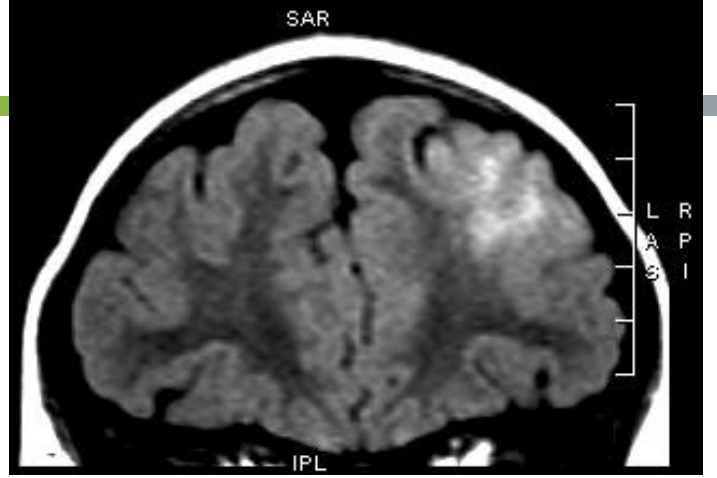
SAR
L R
A P
S I
IPL

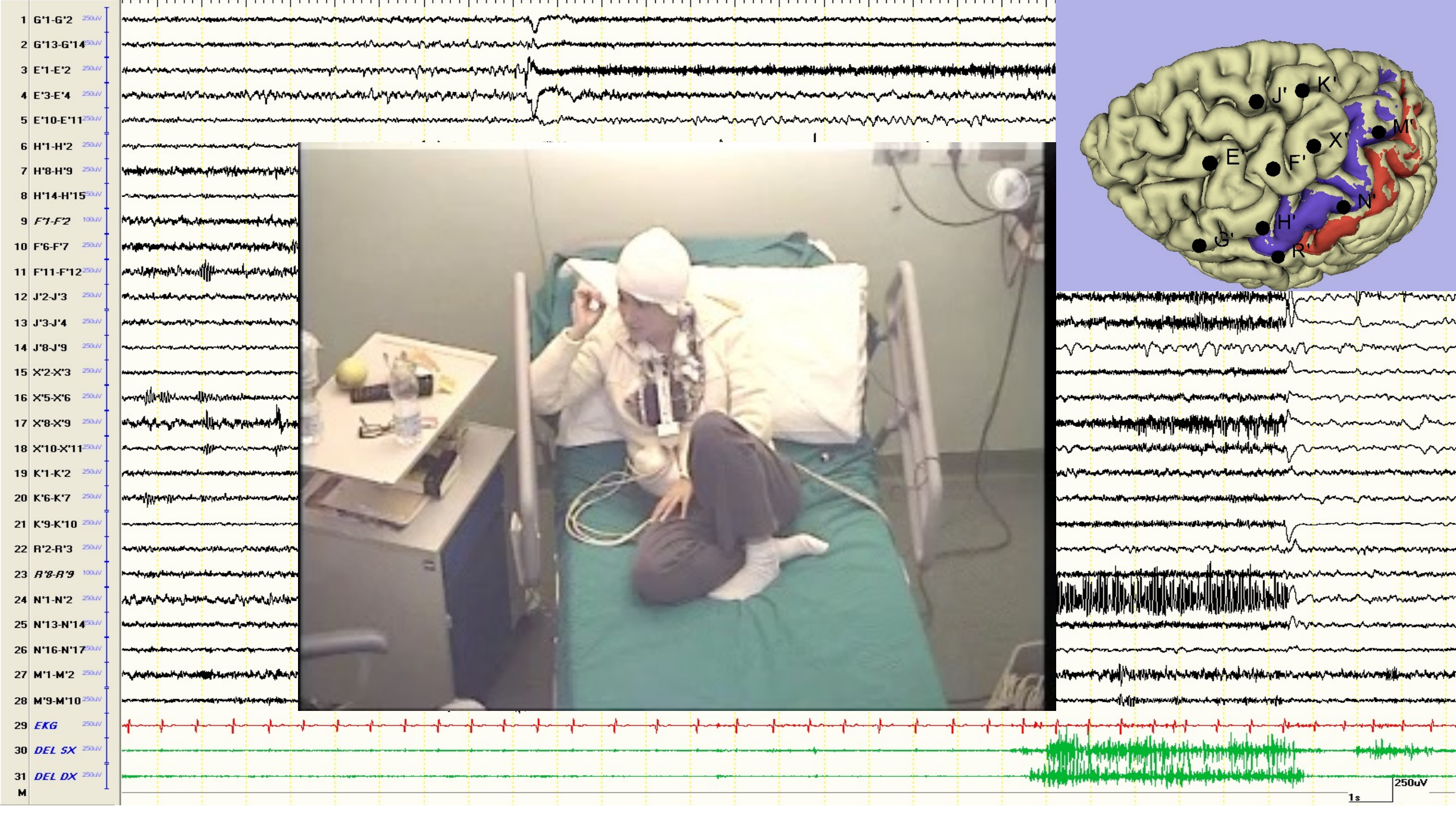
1 G'1-G'2 250uV
2 G'13-G'14 250uV
3 E'1-E'2 250uV
4 E'3-E'4 250uV
5 E'10-E'11 250uV
6 H'1-H'2 250uV
7 H'8-H'9 250uV
8 H'14-H'15 250uV
9 F'1-F'2 100uV
10 F'6-F'7 250uV
11 F'11-F'12 250uV
12 J'2-J'3 250uV
13 J'3-J'4 250uV
14 J'8-J'9 250uV
15 X'2-X'3 250uV
16 X'5-X'6 250uV
17 X'8-X'9 250uV
18 X'10-X'11 250uV
19 K'1-K'2 250uV
20 K'6-K'7 250uV
21 K'9-K'10 250uV
22 R'2-R'3 250uV
23 R'8-R'9 100uV
24 N'1-N'2 250uV
25 N'13-N'14 250uV
26 N'16-N'17 250uV
27 M'1-M'2 250uV
28 M'9-M'10 250uV
29 EKG 250uV
30 DEL SX 250uV
31 DEL DX 250uV
M
J'
K'
M'
X'
E'
F'
N'
H'
G'
R'
250uV
1s

17:07:08

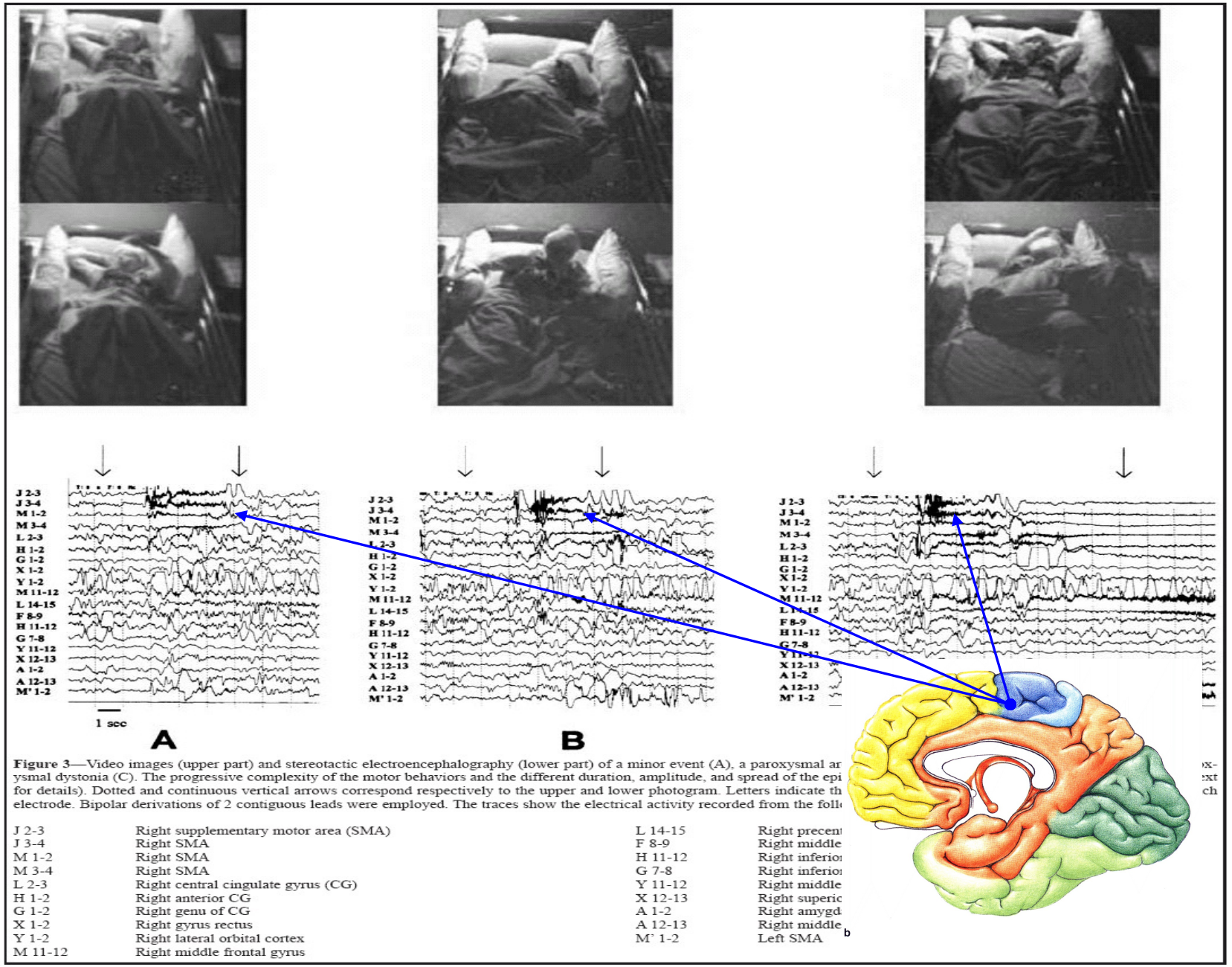

Figure 3—Video images (upper part) and stereotactic electroencephalography (lower part) of a minor event (A), a paroxysmal ar
ysmal dystonia (C). The progressive complexity of the motor behaviors and the different duration, amplitude, and spread of the epi
for details). Dotted and continuous vertical arrows correspond respectively to the upper and lower photogram. Letters indicate th
electrode. Bipolar derivations of 2 contiguous leads were employed. The traces show the electrical activity recorded from the foll

J 2-3	Right supplementary motor area (SMA)	L 14-15	Right precent
J 3-4	Right SMA	F 8-9	Right middle
M 1-2	Right SMA	H 11-12	Right inferio
M 3-4	Right SMA	G 7-8	Right inferio
L 2-3	Right central cingulate gyrus (CG)	Y 11-12	Right middle
H 1-2	Right anterior CG	X 12-13	Right superic
G 1-2	Right genu of CG	A 1-2	Right amygd
X 1-2	Right gyrus rectus	A 12-13	Right middle
Y 1-2	Right lateral orbital cortex	M' 1-2	Left SMA
M 11-12	Right middle frontal gyrus		

b

Nobili et al Sleep 2003

Frontal lobe seizures: From clinical semiology to localization

*†[1]Francesca Bonini, *†‡[1]Aileen McGonigal, *†‡Agnès Trébuchon, *†‡Martine Gavaret, *†‡Fabrice Bartolomei, *†§Bernard Giusiano, and *†‡Patrick Chauvel

Epilepsia, 55(2):264–277, 2014
doi: 10.1111/epi.12490

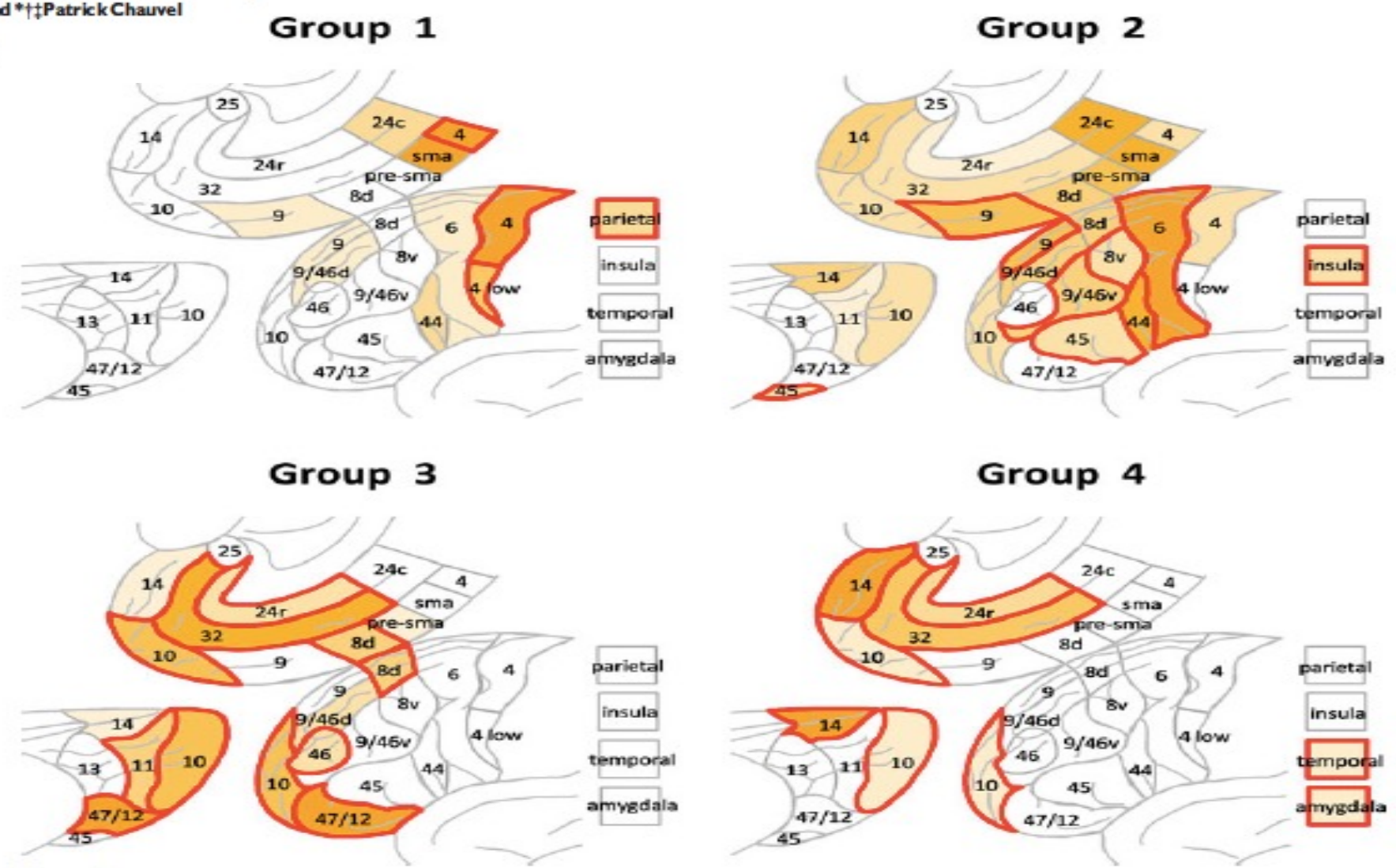

Figure 2.
Cortical regions that characterize the four groups of patients. Brain areas forming part of the early spread network (scored as 2 basing on ictal SEEG) are colored with darker shading, based on the proportion of patients in the group with implication of that area. Brain areas significantly more often involved in one group than the others (value-test > 2) are red bordered. Architectonic subdivision of lateral and medial prefrontal Brodmann areas according to (Petrides & Pandya, 1994).

Epilepsia © ILAE

Frontal lobe seizures: From clinical semiology to localization

*†'Francesca Bonini, *†‡'Aileen McGonigal, *†‡Agnès Trébuchon, *†‡Martine Gavaret, *†‡Fabrice Bartolomei, *†§Bernard Giusiano, and *†‡Patrick Chauvel

Epilepsia, 55(2):264–277, 2014
doi: 10.1111/epi.12490

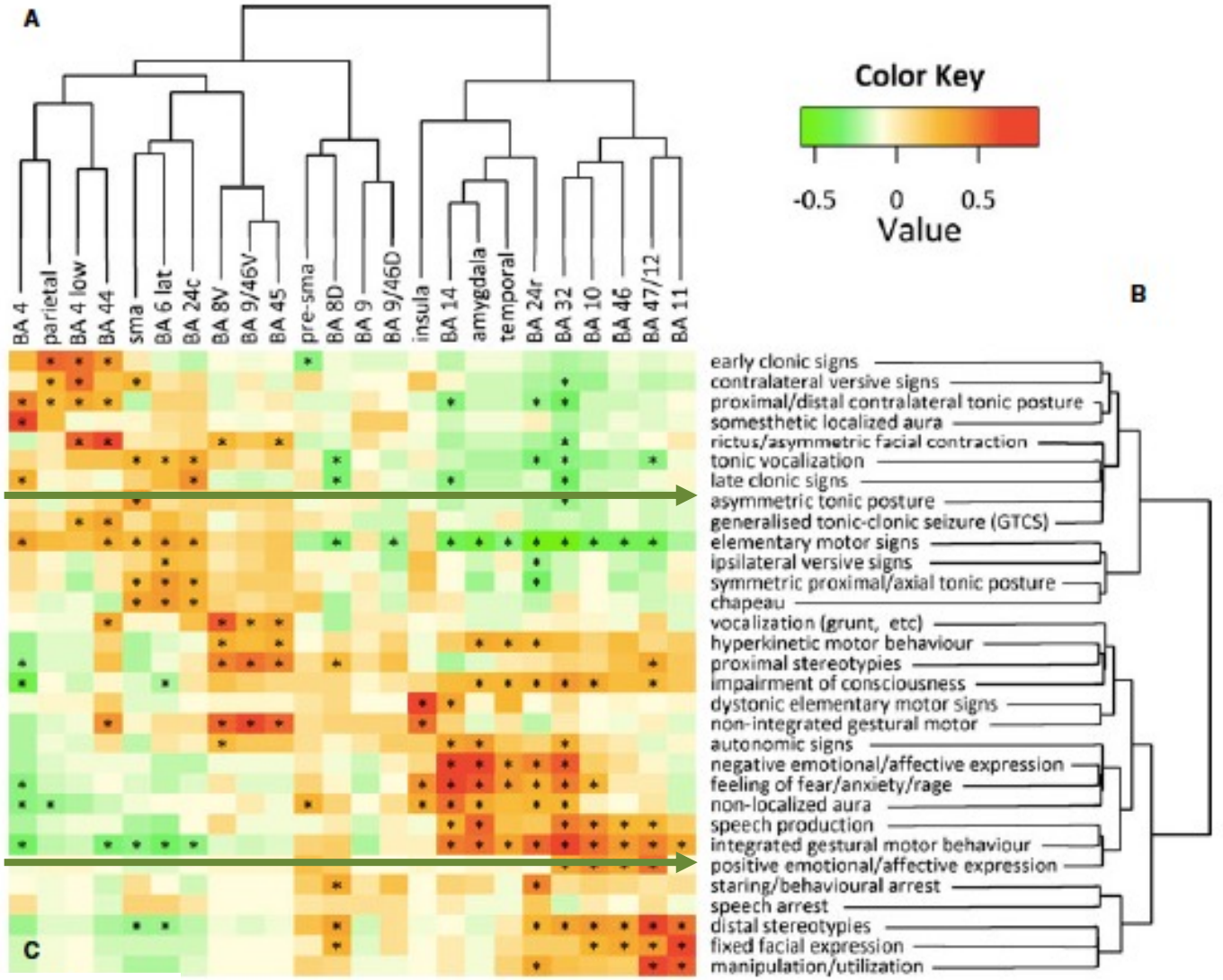

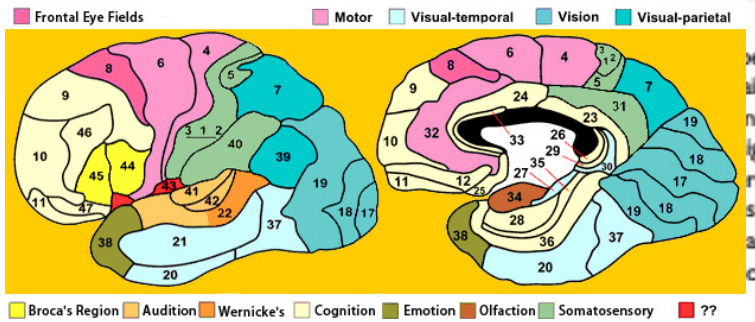

between cortical areas and clinical features, as ordered by hierarchical clustering basing on their reciprocal distance. ain regions is shown on the horizontal axis. (**B**) Clustering of clinical signs is shown on the vertical axis. In these two neighboring regions as well as neighboring signs occur more frequently together than distant ones. (**C**) Correlation igns as a function of the color (red, positive correlation; green, negative correlation; starred squares, $p < 0.05$) fol- rn of association running from more posterior (top left corner) to more anterior regions (bottom right corner). This served for significant correlation ($p < 0.05$ starred squares), indicates the emergence of clinical spectrum developing axis from primary motor cortex to the frontal pole (BA, Brodmann area; SMA, supplementary motor area; pre-SMA, otor area). Architectonic subdivision of lateral and medial prefrontal Brodmann areas according to (Petrides & Pand-

Group 1

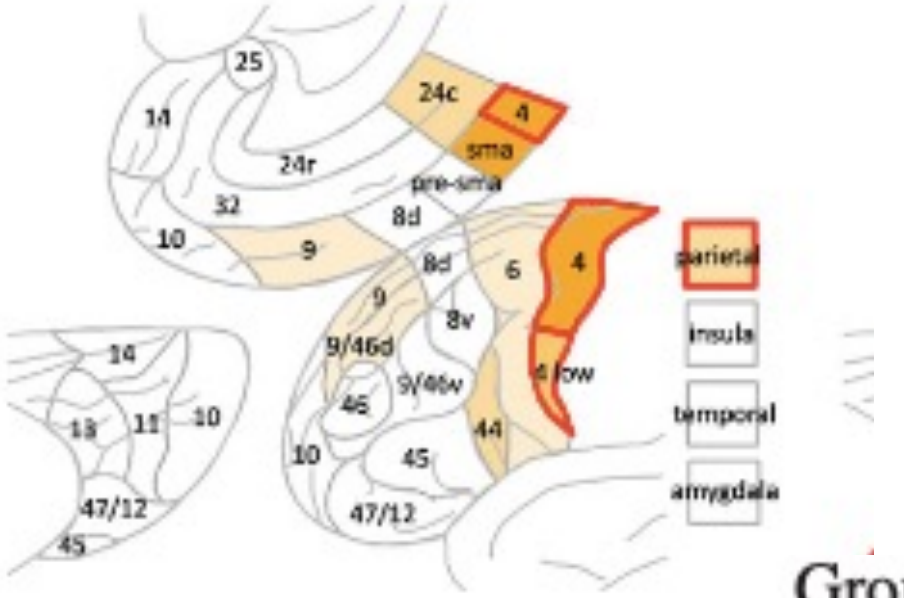

Group 1, composed of 16 patients, is characterized by the presence of one or more of the following elementary motor signs: clonic signs, contralateral tonic posture, contralateral versive signs, asymmetric tonic posture, secondary generalization, or asymmetric facial contraction. Somesthetic localized aura and tonic vocalization could also typically occur in these patients. Moreover, this group is characterized by the absence of gestural motor behavior and of emotional features (Table 1, group 1). Significant involvement

Group 2

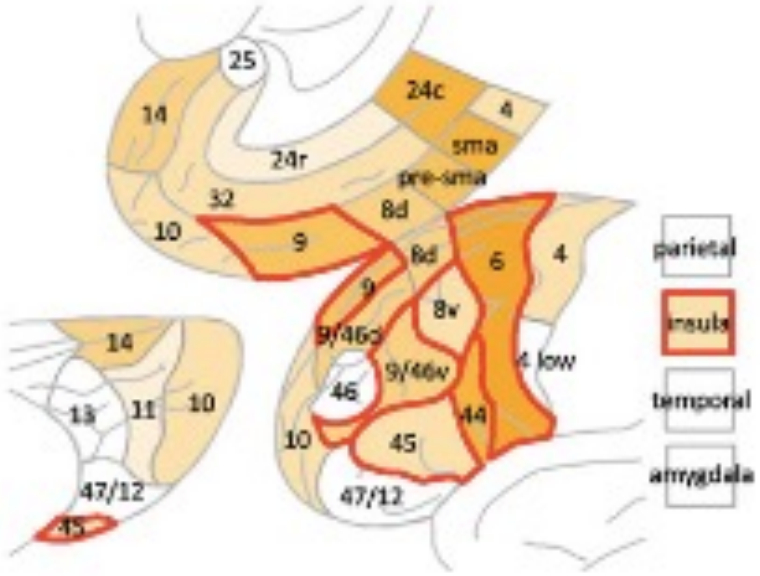

Group 2 (23 patients) was characterized by the co-occurrence of elementary motor signs (typically symmetric axial tonic posture and facial contraction such as "chapeau de gendarme") and nonintegrated gestural motor behavior. In this more heterogeneous group, nonlocalized aura and more complex nonverbal vocalization were also frequently present, whereas integrated gestural motor behavior, distal stereotypies, early clonic signs, and fixed facial expression never occurred (Table 1). Nonintegrated gestural motor behavior could include proximal stereotypies and could have a hyperkinetic character or not (example illustrated in

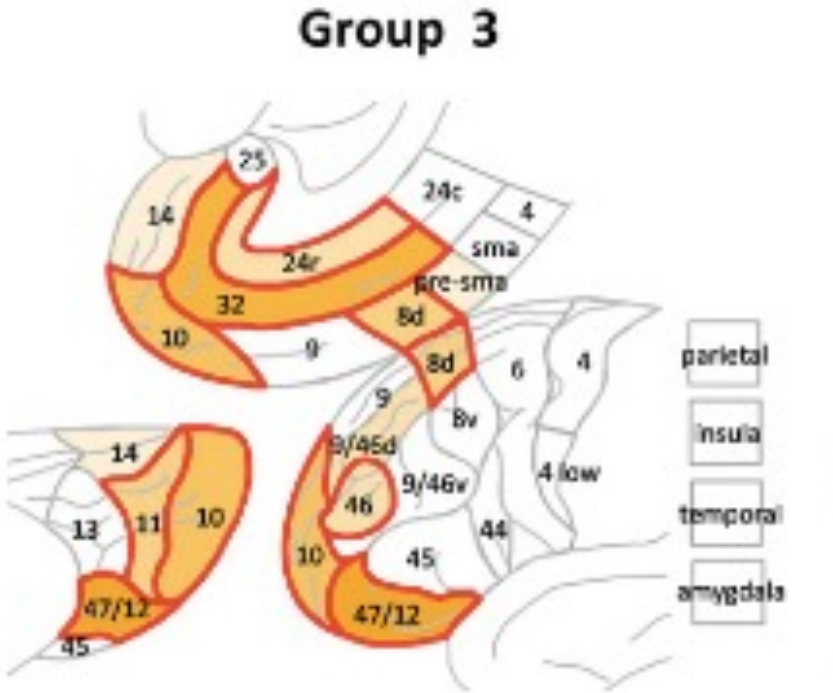

Typical semiologic features of group 3 (10 patients) were the following: integrated gestural motor behavior with distal stereotypies, fixed facial expression or, alternatively, positive emotional expression, proximal stereotypies, and speech production. On the other hand, the absence of any elementary motor sign was a significant characteristic of these patients (Table 1). Early spread network underlying

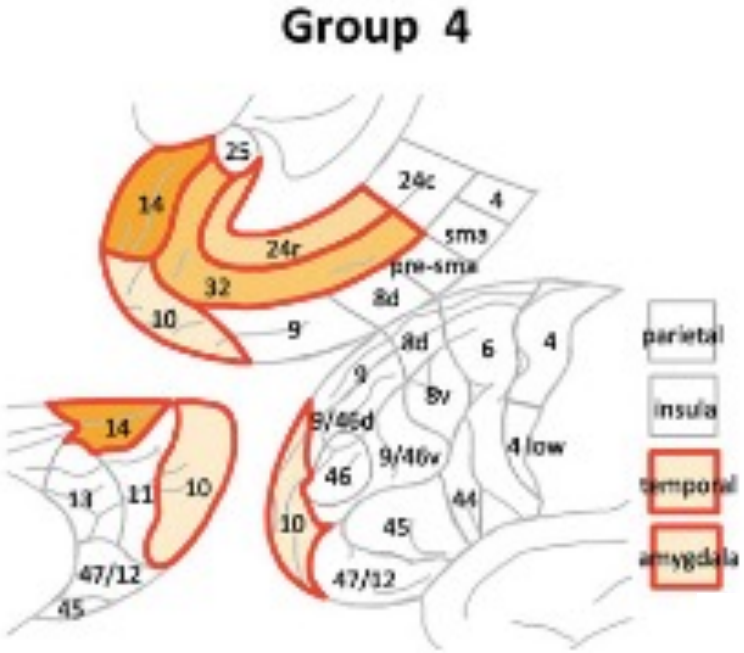

Group 4 was composed of five patients presenting with integrated gestural behavior of fear, sometimes hyperkinetic, with attempt to fight or to escape, frightened facial expression, sometimes screaming or swearing, and autonomic signs. Elementary motor signs never occurred and underlying involved regions corresponded to the orbital and medial-prefrontal network (BA 14, BA 32 and 24r, BA 10) with propagation to amygdala and anterior temporal regions (Fig. 2), but not propagation to lateral frontal cortex.

Epilepsia. 2019 Mar 13

Clinical features of sleep-related hypermotor epilepsy in relation to the seizure-onset zone: A review of 135 surgically treated cases.

Gibbs SA[1,2], Proserpio P[1], Francione S[1], Mai R[1], Cardinale F[1], Sartori I[1], Castana L[1], Plazzi G[3,4], Tinuper P[3,4], Cossu M[1], Russo GL[1], Tassi L[1], Nobili L[1,5].

Sleep-related hypermotor epilepsy (SHE) arises more frequently in the frontal lobe than in the extrafrontal regions. We classified seizure semiology according to four semiology patterns (SPs)

1. elementary motor signs (SP1)
2. unnatural hypermotor movements (SP2)
3. integrated hypermotor movements (SP3)
4. gestural behaviors with high emotional content (SP4).

RESULTS:

Within the frontal lobe, SPs were organized in a posteroanterior gradient (SP1-4) with respect to the SOZ. In temporal SHE, SP1 was rare and SP3-4 frequent, whereas in operculoinsular and posterior SHE, SP4 was absent. Nonmotor manifestations were frequent (70%) and some could provide valuable localizing information.

Epilepsia. 2018 Sep;59(9):e130-e134. doi: 10.1111/epi.14517. Epub 2018 Jul 15.

Seizure duration and latency of hypermotor manifestations distinguish frontal from extrafrontal onset in sleep-related hypermotor epilepsy.

Gibbs SA[1,2], Proserpio P[1], Francione S[1], Mai R[1], Cossu M[1], Tassi L[1], Nobili L[1,3].

Sleep-related hypermotor epilepsy (SHE) is an epilepsy syndrome that is characterized by the occurrence of sleep-related hypermotor seizures of variable complexity and duration. Seizures usually arise in the frontal lobe, but extrafrontal seizure onset zones are well described.

We found that the mean duration of electrographic seizures and clinically observable ictal manifestations were significantly shorter in frontal SHE compared to extrafrontal SHE.

The mean latency between electrographic seizure onset and the onset of hypermotor manifestations was also shorter in frontal SHE. Accordingly, a latency > 5 seconds between the first video-detectable movement (eg, eye opening or a minor motor event) and the onset of hypermotor manifestations yielded a sensitivity of 75% and a specificity of 90% for an extrafrontal onset, thereby indicating that specific ictal features in SHE can provide clinically useful clues to increase diagnostic accuracy in this syndrome.

1. Duration of EEG changes and symptoms shorter in FLE
2. Mean latency EEG → Clinic shorter in FLE
3. Latency EEG → Clinic >5 sec: extraFL origin

Epilepsia, **45**(9):1079–1090, 2004
Blackwell Publishing, Inc.
© 2004 International League Against Epilepsy

Clinical Manifestations of Insular Lobe Seizures: A Stereo-electroencephalographic Study

*Jean Isnard, †Marc Guénot, †Marc Sindou, and *François Mauguière

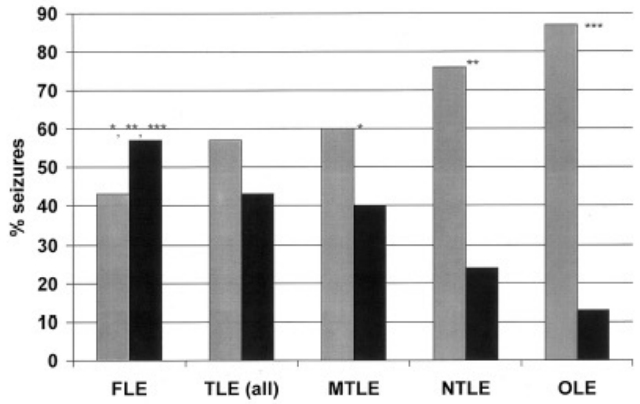

*Figure 2. Percentage of partial seizures arising during sleep from various seizure onset zones. Frontal lobe seizures were more likely to occur during sleep than seizures arising from other foci ($p < 0.0001$). FLE = frontal lobe epilepsy ($n = 112$), TLE = temporal lobe epilepsy ($n = 382$), MTLE = mesial temporal lobe epilepsy ($n = 164$), NTLE = neocortical temporal lobe epilepsy ($n = 54$), OLE = occipital or parietal lobe epilepsy ($n = 45$). Gray bars, awake; black bars, asleep. *$p < 0.05$; ***$p < 0.001$; ***$p < 0.001$.*

Herman, et al
NEUROLOGY 2001;56:1453–1459

Results: This ictal sequence occurred in full consciousness, beginning with a sensation of laryngeal constriction and paresthesiae, often unpleasant, affecting large cutaneous territories, most often at the onset of a complex partial seizure (five of the six patients). It was eventually followed by dysarthric speech and focal motor convulsive symptoms. The insular origin of these

Nocturnal Hypermotor Seizures, Suggesting Frontal Lobe Epilepsy, Can Originate in the Insula

*Philippe Ryvlin, ‡Lorella Minotti, *Geneviève Demarquay, §Edouard Hirsch, ‖Alexis Arzimanoglou, ‡Dominique Hoffman, †Marc Guénot, ¶Fabienne Picard, *Sylvain Rheims, and ‡Philippe Kahane

3 pts	Ryvlin et al., 2006
1 pt	Kaido et al., 2006
1 pt	Dobesberger et al., 2008
1 pt	Nguyen et al., 2009

The ictal EEG

SEEG

VEEG

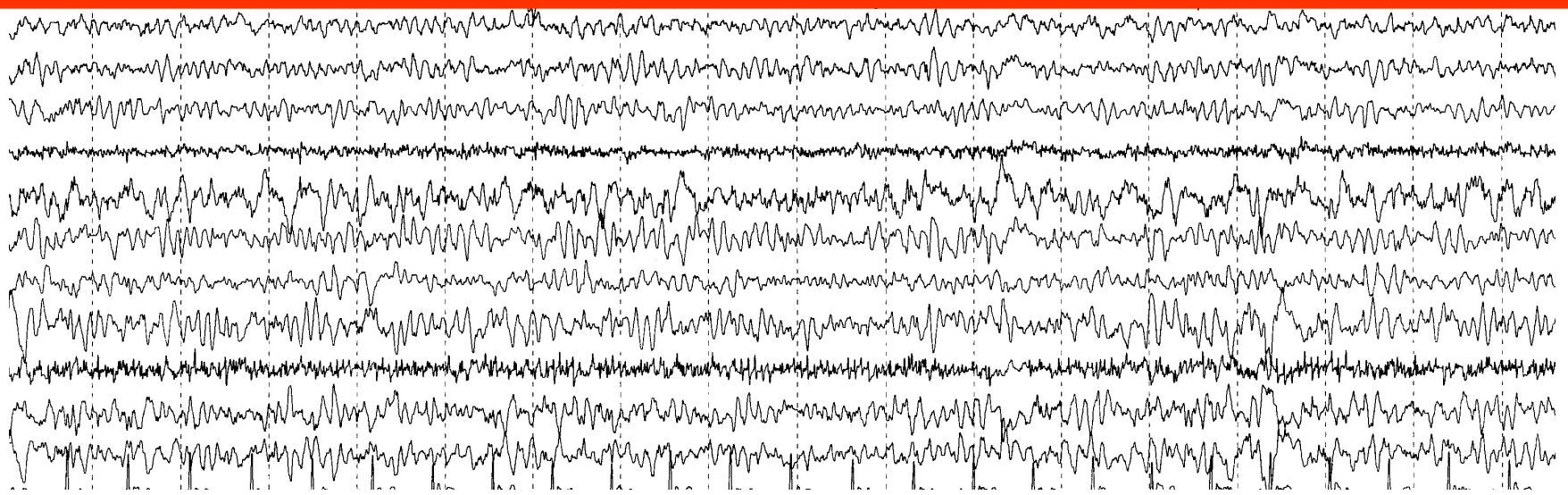

1 O2-O3 100uV
2 O4-O5 100uV
3 O7-O8 100uV
4 O10-O11 100uV
5 Z1-Z2 100uV
6 Z3-Z4 100uV
7 Z10-Z11 100uV
8 Z13-Z14 75uV
9 Z15-Z16 100uV
10 G2-G3 100uV
11 G8-G9 100uV
12 G12-G13 100uV
13 H1-H2 100uV
14 H10-H11 100uV
15 H11-H12 100uV
16 N1-N2 100uV
17 N8-N9 100uV
18 N11-N12 100uV
19 P1-P2 100uV
20 P9-P10 100uV
21 P14-P15 100uV
22 X2-X3 100uV
23 X6-X7 150uV
24 R2-R3 100uV
25 R4-R5 100uV
26 R6-R7 100uV
27 S2-S3 100uV
28 S4-S5 100uV
29 S8-S9 100uV
30 Y3-Y4 100uV
31 Y5-Y6 100uV
32 T1-T2 100uV
33 T3-T4 100uV
34 U2-U3 100uV
35 U7-U8 75uV
36 W1-W2 100uV
37 W7-W8 100uV
38 B2-B3 100uV
40 B13-B14 100uV
41 C2-C3 100uV
42 C4-C5 100uV
43 C10-C11 100uV
44 C13-C14 100uV
45 D1-D2 100uV
46 D3-D4 100uV
47 D7-D8 250uV
48 EKG 375uV
49 DEL SX 250uV
50 DEL DX 250uV
51 EOG 375uV
M



1s 100uV

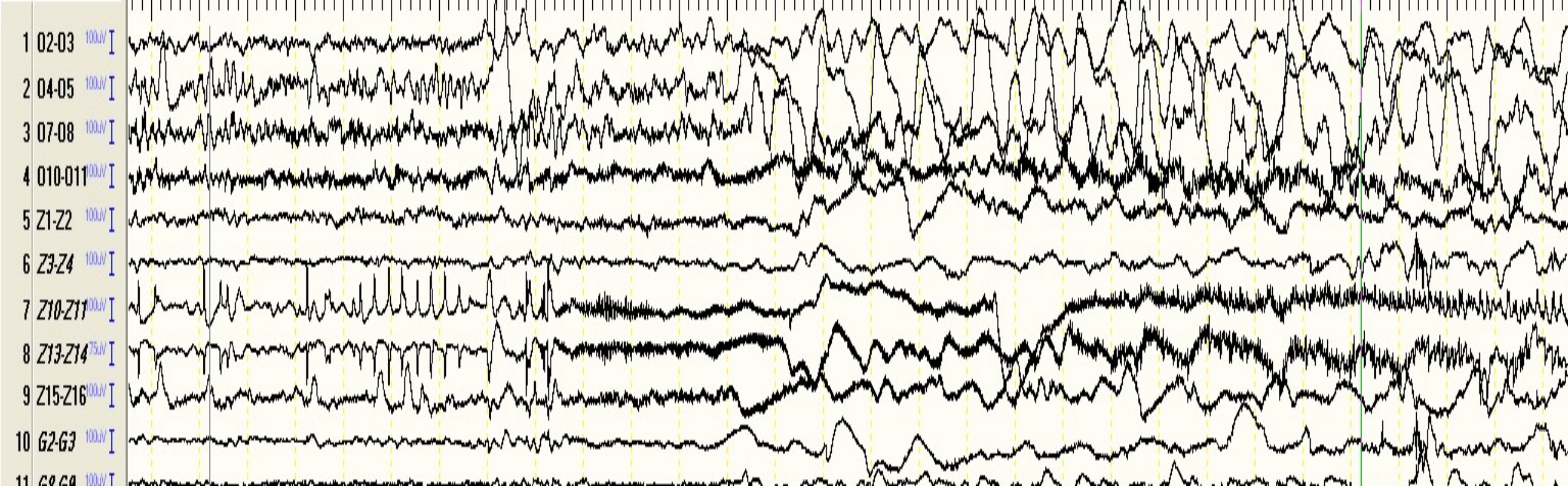
1 02-03 100uV
2 04-05 100uV
3 07-08 100uV
4 010-011 100uV
5 Z1-Z2 100uV
6 Z3-Z4 100uV
7 Z10-Z11 100uV
8 Z13-Z14 75uV
9 Z15-Z16 100uV
10 G2-G3 100uV



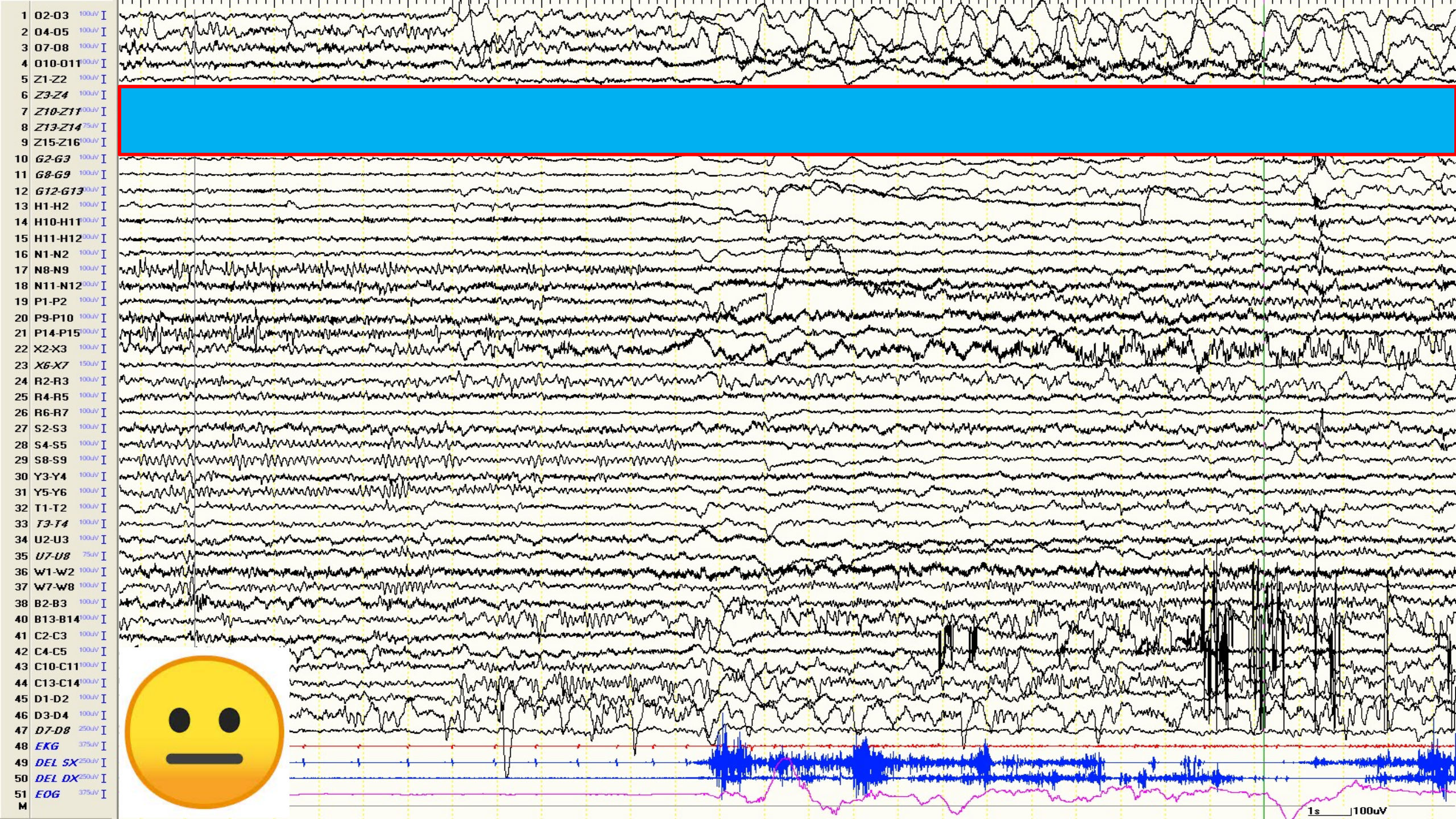
1 O2-O3 100uV
2 O4-O5 100uV
3 O7-O8 100uV
4 O10-O11 100uV
5 Z1-Z2 100uV
6 Z3-Z4 100uV
7 Z10-Z11 100uV
8 Z13-Z14 75uV
9 Z15-Z16 100uV
10 G2-G3 100uV
11 G8-G9 100uV
12 G12-G13 100uV
13 H1-H2 100uV
14 H10-H11 100uV
15 H11-H12 100uV
16 N1-N2 100uV
17 N8-N9 100uV
18 N11-N12 100uV
19 P1-P2 100uV
20 P9-P10 100uV
21 P14-P15 100uV
22 X2-X3 100uV
23 X6-X7 150uV
24 R2-R3 100uV
25 R4-R5 100uV
26 R6-R7 100uV
27 S2-S3 100uV
28 S4-S5 100uV
29 S8-S9 100uV
30 Y3-Y4 100uV
31 Y5-Y6 100uV
32 T1-T2 100uV
33 T3-T4 100uV
34 U2-U3 100uV
35 U7-U8 75uV
36 W1-W2 100uV
37 W7-W8 100uV
38 B2-B3 100uV
40 B13-B14 100uV
41 C2-C3 100uV
42 C4-C5 100uV
43 C10-C11 100uV
44 C13-C14 100uV
45 D1-D2 100uV
46 D3-D4 100uV
47 D7-D8 250uV
48 EKG 375uV
49 DEL SX 250uV
50 DEL DX 250uV
51 EOG 375uV
M
1s
100uV

50 uV | 5.3 Hz | 300 Hz | Traccia | OFF | 15/05/2019 | Trascorso | Epoca
SENS | LF | HF | PAT | RIF | 14:45:56 | 00:08:00 | 49

Piccole — Grandi 12 Inizializza 20 s

1 X'1-X'2
2 X'7-X'8
3 X'10-X'11
4 X'15-X'16
5 Y'1-Y'2
6 Y'10-Y'11
7 G'2-G'3
8 G'8-G'9
9 G'11-G'12
10 O'1-O'2
11 O'6-O'7
12 O'12-O'13
13 I'2-I'3
14 I'8-I'9
15 I'10-I'11
16 A'1-A'2
17 A'11-A'12
18 B'3-B'4
19 B'10-B'11
20 D'2-D'3
21 D'8-D'9
22 D'11-D'12
23 T'1-T'2
24 T'7-T'8
25 U'2-U'3
26 U'7-U'8
27 H'1-H'2
28 H'9-H'10
29 F'1-F'2
30 F'6-F'7
31 F'10-F'11
32 N'1-N'2
33 N'11-N'12
34 S'1-S'2
35 S'6-S'7
36 R'1-R'2
37 R'7-R'8
38 Z'2-Z'3
39 Z'7-Z'8
43 EKG
45 DEL SX
46 DEL DX

Frontal

Temporal

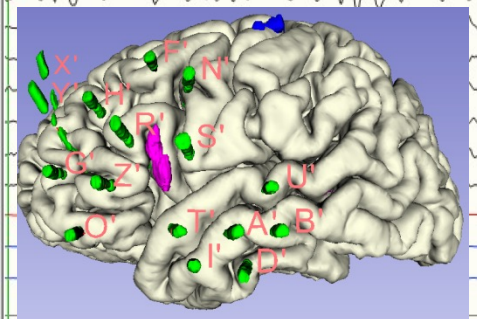

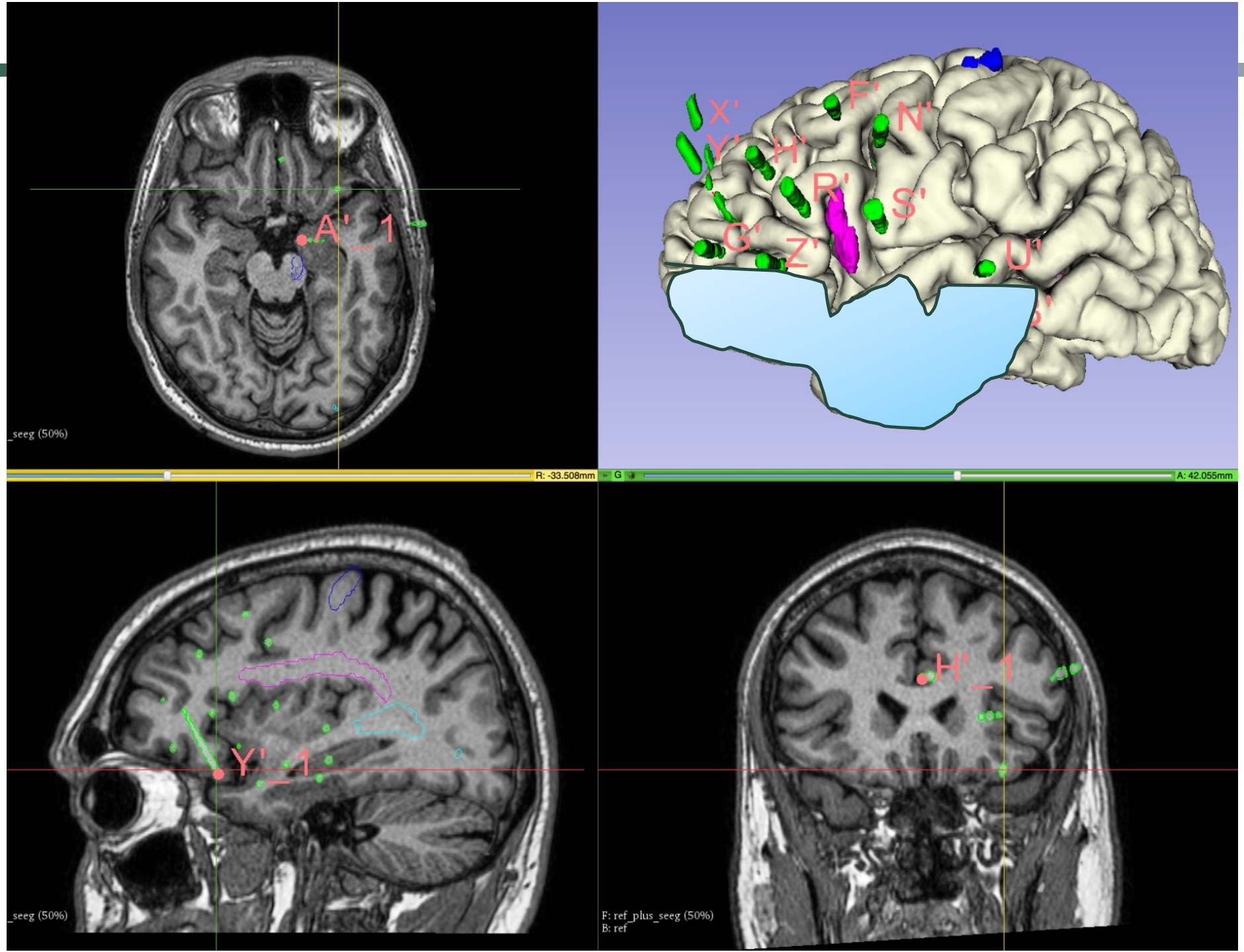
A'_1
_seeg (50%)
X'
Y'
H'
F'
N'
R'
S'
G'
Z'
U'
R: -33.508mm
G
A: 42.055mm
Y'_1
_seeg (50%)
H'_1
F: ref_plus_seeg (50%)
B: ref

1 I'2-I'3
2 I'7-I'8
3 B'2-B'3
4 B'11-B'12
5 C'3-C'4
6 C'11-C'12
7 T'4-T'5
8 T'6-T'7
9 U'2-U'3
10 U'7-U'8
11 Q'2-Q'3
12 Q'6-Q'7
13 Q'9-Q'10
14 X'2-X'3
15 X'4-X'5
16 X'6-X'7
17 R'2-R'3
18 R'7-R'8
19 S'2-S'3
20 S'5-S'6
21 O'3-O'4
22 O'8-O'9
23 O'12-O'13
24 H'2-H'3
25 H'9-H'10
26 N'2-N'3
27 N'15-N'16
28 E'1-E'2
29 E'5-E'6
30 F'1-F'2
31 F'6-F'7
32 J'3-J'4
33 J'7-J'8
34 K'3-K'4
35 K'7-K'8
36 *ECG*
37 DEL SX
38 *DEL SX*
39 *DEL DX*
40 *EOG*
M



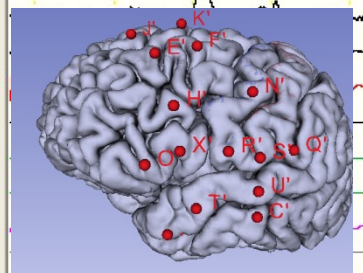

1 Z'2-Z'3
2 Z'9-Z'10
3 Z'12-Z'13
4 L'1-L'2
5 L'9-L'10
6 L'11-L'12
7 R'2-R'3
8 R'4-R'5
9 R'7-R'8
10 G'1-G'2
11 G'9-G'10
12 G'11-G'12
13 E'2-E'3
14 E'7-E'8
15 E'9-E'10
16 F'2-F'3
17 F'4-F'5
18 F'7-F'8
19 J'3-J'4
20 J'9-J'10
21 K'2-K'3
22 K'11-K'12
23 Y'1-Y'2
24 Y'7-Y'8
25 Y'11-Y'12
26 M'1-M'2
27 M'6-M'7
28 M'9-M'10
29 M'10-M'11
30 N'1-N'2
31 N'13-N'14
32 N'15-N'16
33 T'1-T'2
34 I'2-I'3
35 I'3-I'4
36 I'7-I'8
37 B'3-B'4
38 B'13-B'14
39 O1-O2
40 O9-O10
41 E2-E3
42 *E10-E11*
43 F2-F3
44 F7-F8
45 *E-KG*
M



1 Z'2-Z'3
2 Z'9-Z'10
3 Z'12-Z'13
4 L'1-L'2
5 L'9-L'10
6 L'11-L'12
7 R'2-R'3
8 R'4-R'5
9 R'7-R'8
10 G'1-G'2
11 G'9-G'10
12 G'12-G'13
13 E'2-E'3
14 E'7-E'8
15 E'9-E'10
16 F'2-F'3
17 F'4-F'5
18 F'7-F'8
19 J'3-J'4
20 J'9-J'10
21 K'2-K'3
22 K'11-K'12
23 Y'1-Y'2
24 Y'7-Y'8
25 Y'11-Y'12
26 M'1-M'2
27 M'6-M'7
28 M'9-M'10
29 M'10-M'1
30 N'1-N'2
31 N'13-N'14
32 N'15-N'16
33 T'1-T'2
34 I'2-I'3
35 I'3-I'4
36 I'7-I'8
37 B'3-B'4
38 B'13-B'14
39 O1-O2
40 O9-O10
41 E2-E3
42 *E10-E11*
43 F2-F3
44 F7-F8
45 *E-KG*
M

CONCLUSIONS

- **Huge lobe, very well connected, mimicking semeiology.**
- **Ictal symptoms depend on etiology, localization, age.**
- **The localizing diagnosis is based on anatomo-electro-clinical data.**
- **Clinical manifestations chronology is mandatory.**
- **Very difficult interictal and ictal EEG.**


Never ever give up!

Claudio Munari Center

Clinical Neurophysiology

Stefano Francione
Francesca Gozzo
Roberto Mai
Lino Nobili
Veronica Pelliccia
Ivana Sartori

Functional Neurosurgery

Francesco Cardinale
Laura Castana
Massimo Cossu
Giorgio Lo Russo

Monitoring Unit

Antonio Menna
Alessandra Ramaiola
Maurizio Rossi
Katrina Sambusida
Fabrizio Sandrin
Claudia Vilasi

Neuroradiology

Alberto Citterio
Nadia Colombo

Neuropathology

Manuela Bramerio
Carlo Galli
Roberto Spreafico

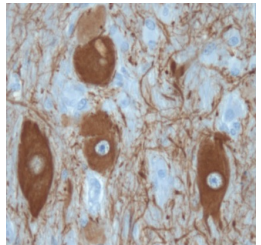

Neuropsychology

Gabriella Bottini
Pina Scarpa

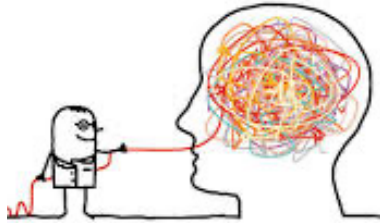

Physics
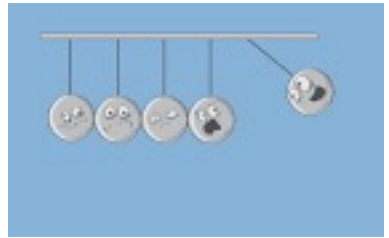
Paola Colombo
Alberto Torresin